

Review

Infection and vasculitis

Cristina C. Belizna¹, Mohamed A. Hamidou², Hervé Levesque¹, Loic Guillevin³ and Yehuda Shoenfeld⁴

Vasculitis may be associated with infection, immunization or anti-microbial drugs. Infections are responsible for a number of different types of vasculitis. Conversely, patients with vasculitis may develop infections, which sometimes mimic relapse. The aim of this review is to summarize the various aspects of the inter-relationship between vasculitis and infection, and the physiopathological mechanisms involved, in light of our current knowledge from animal models. Currently, a causal relationship between infection and vasculitis has only been established in a few instances and many mechanisms remain hypothetical. This inter-relationship is further assessed from the point of view of clinical presentation and therapeutic options, based on case reports and prospective observational data.

KEY WORDS: Infection, Vasculitis, Autoimmune, Immune mechanism, Animal model.

Introduction

The relationship between infection and vasculitis is complex [1]. Taking into consideration examples of historical diseases such as tuberculous or syphilitic aortitis, infections have long been suspected to be trigger factors for many types of vasculitis. However, a causal relationship has only been firmly established in a few instances using an epidemiological approach (e.g. PAN and HBV; cryoglobulinaemia and HCV). In most cases, however, this link remains hypothetical without formal evidence. The physiopathology of this inter-relationship remains poorly understood.

Animal models of vasculitis

Immune and autoimmune mechanisms are both responsible for vasculitis. Recently, antibodies such as ANCA and/or some key components of apoptosis have been found to be involved in the pathogenesis of various types of vasculitis in animal models. An important contribution to this field has been the use of a mouse model of ANCA-associated vasculitis [2]. Huugen *et al.* [2] used a model of passive transfer of anti-MPO antibodies prepared in MPO knock-out mice. They transferred the anti-MPO IgG to naïve C57BL/6 mice (control mice received anti-BSA antibodies). One hour after the administration of anti-MPO, bacterial lipopolysaccharide (LPS) was also injected intraperitoneally in some mice. Clinical manifestations (haematuria and leucocyturia) and pathological findings (necrotic crescentic glomerulonephritis) were more severe in mice receiving LPS, suggesting that LPS is an aggravating factor in anti-MPO vasculitis [2].

Some authors recently reported severe lung granulomatous vasculitis after intravenous injection of Fas ligand in a murine animal model [3].

There are also some other experimental animal models of vasculitis which suggest that infection could be a trigger in vasculitis and/or interfere with different immune mechanisms. These include parvovirus infection in Aleutian mink leading to vasculitis similar to human PAN, and epidemic equine coronavirus infection,

which is followed by endothelial infection with local inflammation and fibrinoid necrosis [4, 5].

Furthermore, when streptococcal toxins were injected into the ear arteries of rabbits, a vasculitic syndrome was induced [6]. *Chlamydia pneumoniae* was shown to induce aortic vasculitis in rabbits [7] and RNA virus and/or herpes virus produced aortitis and/or Behçet's disease in inbred mouse strains [8, 9].

Vasculitis of the great vessels has been described in mice lacking INF- γ responsiveness, and immunohistochemical studies showed that γ -herpes virus 68 infection in mice was followed by severe panarteritis [10]. However, although γ -herpes virus 68 has a high tropism for the media of the elastic arteries (a site that seems to allow the persistence of pathogens), this vasculitis is limited by IFN- γ [10].

Recently, Paessler *et al.* [11] described an animal model of eastern equine encephalitis. Infection of golden hamsters with eastern equine encephalitis virus, responsible for the most severe human arboviral diseases in the USA, resulted in histological findings of vasculitis with cerebral micro-haemorrhages similar to those described in humans.

Mechanisms of vasculitis

Several mechanisms could be involved in primary vasculitis related to infections [12, 13].

- (i) A type III or immune complex reaction where the antigens are the infectious agents or antigenic portions of them [14]: after the zone of equivalence is reached, the immune complexes precipitate and become trapped within vessel walls, stimulating an immune response that leads to vascular injury.

Candida polysaccharides and fragments of Gram-positive and Gram-negative organisms can activate the alternate pathway and also lead to the inflammatory reaction characteristic of vasculitis [14–16].

Vasculitis resulting from the deposition of circulating immune complexes is represented by PAN associated with HBV infection, cryoglobulinaemia associated with systemic vasculitides, mainly the consequence of HCV infection, and HSP, which results from the deposition in the mesangium and vessels of IgA forming complexes.

Histology reveals mainly the deposition of immune complexes formed from viral antigens and from antibodies responsible for the activation of the classic complement pathway and for recruitment of neutrophils (i.e. PAN associated with HBV infection).

¹Internal Medicine Department, CHU Rouen, Rouen, ²Internal Medicine A Department, CHU Hôtel Dieu, Nantes, ³Internal Medicine Department, Hôpital Cochin, Assistance Publique-Hôpitaux de Paris, Paris, France and ⁴Department of Medicine 'B' and Center for Autoimmune Diseases, Sheba Medical Center, Tel Aviv University, Tel Hashomer, Israel.

Submitted 8 October 2007; revised version accepted 21 January 2009.

Correspondence to: Cristina C. Belizna, Internal Medicine A Department, CHU Rouen, 147 Avenue du Maréchal Juin, 76000 Rouen, France.
E-mail: cristina.belizna@wanadoo.fr

Cryoglobulinaemia has been reported in HIV-1-infected patients [17], and considered to be associated with an increased death risk and/or neoplasia [18].

However, the production of circulating cryoglobulins does not seem to be related to HIV infection, but strongly correlates with HCV coinfection and liver cirrhosis [19].

Recently, features of cryoglobulinaemia vasculitis were studied in HIV and HCV coinfecting patients. Therefore, coinfecting patients had higher liver inflammation and higher gammaglobulinaemia, but lower cryoglobulin level [20]. Moreover, anti-HCV therapy was beneficial in this population [20].

Associated HIV infection significantly reduced the clinical and immunological expression of cryoglobulinaemia, except in coinfecting patients with high viral loads for the both viruses [21].

Cryoglobulinaemia was further studied in coinfecting patients in relation to their CD4 cell count by Aaron *et al.*, and resulting data suggest that cell-mediated immunity could contribute to the production of HCV-associated cryoglobulins [22].

- (ii) Cell-mediated hypersensitivity: antigenic exposure may attract lymphocytes which liberate cytokines causing tissue damage and further activation of macrophages and lymphocytes (GCA).

In GCA for instance, the exposure to antigens (probably infectious, but no clear evidence supports this data) triggers a T-cell driven process leading to vasculitis. Dendritic cells from the vascular wall are potent antigen-presenting cells and therefore are able to activate CD4⁺ T cells, which will be further responsible for macrophage and monocyte recruitment to the vessel wall [23].

These cells will release several cytokines (IL-1 and -6) and tissue-resident T cells release IFN- γ , which is a key pro-inflammatory cytokine that has been implicated in the pathogenesis of GCA. Sustained inflammation mediated by T cells, macrophages and the pro-inflammatory cytokines leads to intimal thickening and vessel occlusion. Platelet-derived growth factor and vascular endothelial growth factor also play important roles in the subsequent development of the lumen-occlusive arteritis.

- (iii) Abnormal immune regulation (some vasculitis in HIV patients with advanced disease): in most vasculitis syndromes there is an abnormal expression of adhesion molecules and cytokines in vascular endothelium as a manifestation of an endothelial dysfunction that can be triggered by a variety of stimuli (including infectious agents, immune complexes and anti-endothelial cell antibodies).
- (iv) Direct endothelial cell invasion can be the main pathogenic process in infections caused by CMV, herpes simplex, rickettsiae, fungi and bacteria [15, 16].
- (v) Recent data suggest other mechanisms in the development of vasculitis within the context of infection [24]. Cytokines, such as TNF and various ILs, are produced directly by the stimulation from the infectious agents. Subsequently, recruitment of neutrophils to the small vessels occurs and leads to the development of vasculitis. Vasculitis related to infection due to streptococcus and staphylococcus has been associated with this mechanism of vascular injury.

Primary vasculitis and infection

PAN

PAN and its association with HBV is a classical example of primary vasculitis related to an infectious agent [25, 26]. There is no reliable animal model for PAN related to HBV, but virological and prevalence studies support a formal causality.

The association between PAN and HBV has been reported frequently (10–54%) [27–30], usually within the first 6 months after HBV infection. Over recent years there has been an important decrease in HBV-PAN [31], primarily due to HBV

TABLE 1. Infectious agents and PAN

Infectious agent	Frequency of association (references)	Supporting data
HBV	Strong [27–30]	Prevalence studies, virological
<i>Streptococcus β-haemolyticus</i>	Possible [33–35]	Anecdotal case reports
<i>Klebsiella</i>	Weak [36]	Anecdotal case reports
<i>Pseudomonas</i>	Weak [36]	Anecdotal case reports
<i>Yersinia</i>	Weak [37]	Anecdotal case reports
HIV	Weak [38–40]	Anecdotal case reports
Parvovirus B19	Weak [41, 42]	Anecdotal case reports
VZV	Weak [43]	Anecdotal case reports
<i>Echinococcus</i>	Weak [44, 45]	Anecdotal case reports
<i>Trichinella</i>	Weak [44, 46]	Anecdotal case reports
<i>Ascaris</i>	Weak [44, 45]	Anecdotal case reports

VZV: Varicella zoster virus.

vaccination and full pre-transfusional blood screening. Minor clinical differences have been noticed in HBV-PAN compared with non-infectious PAN including a dramatic onset, a milder favourable clinical course and seroconversion followed by complete healing. Biology in HBV-PAN reveals constant viral replication, HBsAg (7–36% of the cases) and inconstant immune complexes. Less than 10% of the cases of PAN are associated with HCV. In a retrospective study, important clinico-pathological features and therapeutic differences were found between HCV-PAN vasculitis and HCV-cryoglobulinaemia [32].

Some other infectious agents are reported in PAN, but without formal evidence data (Table 1).

A distinction should be done between PAN and HBV-related PAN, since there are important differences in pathogenesis with further consequences on treatment and prognosis.

INF- α and vidarabine used in a prospective, uncontrolled study resulted in improvements in survival and seroconversion in >50% of the cases [47]. Furthermore, Guillevin *et al.* [48, 49] demonstrated that short-term corticosteroids, plasma exchange and antiviral therapy in HBV-PAN were effective and safe.

Cryoglobulinaemia

The majority of the cases of cryoglobulinaemia are HCV related, and this link has been established since several years [50]. Further studies have shown that mixed cryoglobulinaemia is common in chronic HCV infection and is predominantly of type II [51]. Data from serological and virological investigations support a pathophysiological role for HCV infection in cryoglobulinaemia: positive anti-HCV testing (80–90% of the patients), circulating HCV-RNA, HCV in lesions and HCV-RNA in cryoprecipitate.

Furthermore, Sansonno *et al.* [52] have shown that HCV-RNA levels in circulating lymphocytes from patients with mixed cryoglobulinaemia are significantly higher compared with those observed in non-cryoglobulinaemic patients.

Recent data have identified the 1b HCV genotype as the genotype most frequently associated with cryoglobulinaemia, while genotypes 2–3 are associated with cryoglobulinaemia in coinfecting HIV–HCV patients. The symptoms in cryoglobulinaemia related to HCV are mainly cutaneous, rheumatological and renal. However, there is no correlation between liver disease activity score and cryoglobulinaemia. The reported prevalence of cryoglobulins was 45.7% in HCV patients and the prevalence of symptoms associated with the presence of cryoglobulins was 27% [53].

Cryoglobulinaemia can also be secondary to HBV infection and the relationship between HBV and cryoglobulinaemia has been established since the detection of HBV in type III cryoglobulinaemia [54].

Levo [55] found HBV markers (HBsAg or its antibody) in cryoprecipitates in two-thirds (74% or 14/19) of their patients with mixed cryoglobulinaemia not related to lymphoproliferative disease or CTD. In serum specimens, 3 of the 25 sera were

TABLE 2. Infectious agents and cryoglobulinaemia

Infectious agent	Frequency of association	Supporting data
HCV	Strong [50–52]	Epidemiological, serological, virological
HBV	Possible [54, 55]	Epidemiological
HIV	Possible [18, 23]	Prevalence and virological studies
CMV	Weak [61–63]	Anecdotal cases
EBV	Weak [64]	Anecdotal cases
Parvovirus B19	Weak [59, 63, 65]	Anecdotal cases

positive for HBsAg (12%), and 12 had anti-HBV antibodies (48%) [55].

HBV and HCV have similar epidemiological characteristics, but the few cases of cryoglobulinaemia associated with HBV infection reported in the literature do not enable a determination of the precise role of coinfection with HCV [56].

In a series of 154 consecutive patients, the prevalence of cryoglobulins was found to be significantly higher ($P < 0.001$) in HCV patients (46%) than in HBV patients (13.4%) [57].

Cryoglobulinaemia has occasionally been reported after HIV, CMV, EBV and parvovirus B19 infection, but there are only sporadic reports and no formal conclusion could be drawn [57–59] (Table 2).

A recent study in HIV-infected subjects however showed that this virus does not play an important role in the production of cryoglobulins [60].

In 1994, Misiani *et al.* [66] reported the benefits of INF- α vs no INF in a prospective, randomized, controlled trial: in the treated population, circulating HCV-RNA disappeared in 60% of the cases. Since the successful treatment of HCV-associated cryoglobulinaemic glomerulonephritis [67], a protocol combining INF- α and ribavirin could be considered for HCV-cryoglobulinaemia. However, nowadays, some new therapies such as anti-CD20 monoclonal antibody administration are also discussed as treatment in these patients [68].

WG

Several data suggest an autoimmune and infectious pathogenesis in WG, a disease characterized by permanent T-cell activation: flare-ups are initiated by respiratory tract infections and circulating immune complexes [69], with the presence of granuloma [70]. Nowadays there is no clear evidence for an infectious trigger in WG, although several reports support that *Staphylococcus aureus* has a major role. The relationship between *S. aureus* and WG was first suggested by Wegener *et al.* and is supported by recent data. Stegeman *et al.* [71] demonstrated a strong association between *S. aureus* carriage and WG relapse, and selective reactivity of T-cell clones to *S. aureus* was reported. Prolonged administration of cotrimoxazole diminished relapse rates [72] and was efficient in cases unresponsive to other treatments, suggesting either an immunosuppressive effect via folic acid antagonism, or an infectious trigger for relapses [73].

Infections may play several roles in WG. Therefore, some mediators of inflammation such as TNF- α are locally released, inducing endothelial cell activation and neutrophil priming, and further ANCA-mediated PMN activation.

Cell-wall components of *S. aureus* represent powerful mitogens that can stimulate auto-reactive B cells to produce ANCA.

It has been suggested that *S. aureus* phosphatase acts as a 'planted' antigen and initiates glomerulonephritis and vasculitis [74].

In addition, microbial antigens may act as superantigens, causing selective expansion of T cells bearing particular TCR V β chain variable regions. Some authors reported abnormal expansion of T cells, using V α and V β gene products, and other groups observed increased V β 2.1 gene usage in vasculitis.

TABLE 3. Infectious agents and WG

Infectious agent	Frequency of association	Supporting data
<i>Staphylococcus aureus</i>	Possible [69–71]	Serological, virological
Parvovirus B19	Weak [76, 77]	Anecdotal cases
<i>Nocardia</i>	Weak [78]	Anecdotal cases

TABLE 4. Infectious agents and KD

Putative aetiological agent	Frequency of association	Supporting data
Adenovirus	Weak [79]	Anecdotal
Herpes virus	Weak [80]	Anecdotal
<i>Mycoplasma</i> species	Weak [81]	Anecdotal
Toxigenic streptococci	Weak [82, 83]	Anecdotal
Toxigenic staphylococci	Weak [83–85]	Anecdotal
<i>Propionibacterium acnes</i>	Weak [86]	Anecdotal
<i>Ehrlichia chaffeensis</i>	Weak [87, 88]	Anecdotal
<i>Rickettsia</i> species	Weak [89, 90]	Anecdotal
EBV	Weak [91, 92]	Anecdotal
Retrovirus	Weak [93, 94]	Anecdotal
Human coronavirus New Haven	Weak [95]	Anecdotal
Measles virus	Weak [96, 97]	Anecdotal
<i>Chlamydia pneumoniae</i>	Weak [98, 99]	Anecdotal
<i>Bartonella henselae</i>	Weak [100]	Anecdotal
<i>Coxiella burnetii</i>	Weak [101, 102]	Anecdotal
<i>Lactobacillus</i>	Possible [103]	Experimental
<i>Candida</i>	Possible [104]	Experimental

However, a recent study [75] contests *S. aureus* superantigenic activity: despite production of superantigenic toxins by nasal carriage of *S. aureus*, there was no peripheral T-lymphocyte repertoire bias found.

In addition to *S. aureus* several other infectious agents have also been reported in WG, but without any consistent evidence (Table 3).

In the case of parvovirus B19-related WG, the main dilemma is whether this pathogen represents an aetiological agent or if it leads to opportunistic infection [76, 77]. The relationship between *Nocardia* and WG is also unclear. There is one reported case of *Nocardia* infection mimicking the WG triad [78], but also cases where *Nocardia* infection appeared during WG evolution, due to the immunosuppression present in this disease.

Kawasaki disease

An infectious aetiology has been suspected in Kawasaki disease (KD), based mainly on its epidemiological characteristics and clinical multisystemic presentation. Therefore, KD displays an age distribution similar to other childhood infections, and is more common in boys (male:female ratio 1.6:1) as observed in many infectious diseases where sex differences in immune responses are suggested to mediate susceptibility. Seasonal variation in KD incidence is observed in different geographical regions, and furthermore the clinical features of the disease are also characteristic of a severe acute childhood infection.

All these epidemiological data could suggest an infectious aetiology for KD.

Several pathogens have been reported in this disease, but without any clear evidence for their contribution to pathogenesis (Table 4).

Laboratory techniques (microbiological, molecular and serological methods) were so far unable to identify an aetiological agent. Molecular techniques fail to detect circulating conserved microbial sequences in KD, suggesting either that the antigenic stimulus may arise from a distant site and/or may be a host-derived factor involved in the pro-inflammatory cascade.

However, the possibility of environmental factors influencing aetiology, possibly by modulating infection risk, remains, as suggested by some animal models.

Hence, it has been shown that microbial components from *Lactobacillus* and/or *Candida*, injected in animal models, induced coronary arteritis. Lehman *et al.* [103] immunized several mouse strains with intraperitoneal injection of *Lactobacillus* case cell wall extract (LCWE) and observed coronary arteritis 3 days after the immunization [103]. In a similar manner, *Candida albicans* water soluble fraction infused intraperitoneally in several mouse strains induced coronary vasculitis, associated with a high production of IL-6 and IFN- γ [104].

A superantigenic mechanism has been suggested, which may be related to an infectious agent, since KD shares many clinical features with superantigen-mediated diseases and has occasionally been reported concurrently in children with toxic shock syndrome, which is caused by superantigens [105]. Superantigens bind to the V β region of the TCR and clonal expansion of V β 2-expressing T cells has been observed by some authors in KD [105], but this finding is inconsistent [106].

Duong *et al.* [107] used a similar model with LCWE but with genetically modified mice expressing human CD4 and human MHC Class II DQ6 transgenes in a background lacking endogenous CD4 and CD8. They observed that these mice displayed human-like responsiveness to bacterial antigens, and further *in vitro* studies have shown a superantigenic activity in the LCWE fraction that was directly correlated with the capacity of LCWE to induce coronary lesions. Furthermore, using the same animal model, Hui-Yuen *et al.* [108] reported that a TNF blocker (etanercept) could prevent the development of arteritis, suggesting the role of pro-inflammatory cytokines in the pathogenesis of KD.

Epidemiological and laboratory data supporting the infectious superantigenic hypothesis are lacking, although these data may reflect the involvement of as yet unidentified superantigen in humans [106].

Furthermore, a combined (antigenic and superantigenic) mechanism has been proposed [109].

Nevertheless, the pathogenic mechanisms in KD seem to be multifactorial, requiring certain immunological and genetic factors, and probably a vector.

Takayasu arteritis

Although the aetiopathogenesis of Takayasu arteritis (TA) is unknown, the increased number of activated circulating T cells and their localization in vascular lesions suggest that T cells are implicated in the initiation of the disease. Nevertheless, the putative trigger antigen(s) are still unknown. For long *Mycobacterium tuberculosis* has been thought to be a possible aetiological agent in TA but there is no convincing data for this, except one study [110].

Although several clinical studies were unable to find a correlation between infection and this vasculitis, some data concerning the implication of infectious agents in TA came from animal models. Fong *et al.* [111] and Laitinen *et al.* [112] reported aortic inflammation after *C. pneumoniae* infection, and observed bacterial antigen in intimal endothelial cells by immunohistochemistry.

RNA virus [porcine reproductive and respiratory syndrome virus (PRRSV)] and herpes virus were also found to induce vessel inflammatory lesions in pig and, respectively, mouse models. Rossow *et al.* [113] reported a multifocal systemic disease and Cooper *et al.* [114] renal vascular lesions after PRRSV infection. Several mouse strains infected with murine CMV (MCMV) disclosed aortic inflammation with mononuclear cells in the intima and adventitia, cytomegalic inclusion bodies in the smooth muscle cells and MCMV antigen on immunohistochemistry [115, 116].

Panarteritis with mononuclear infiltrates in the adventitia and media has been found in an IFN- γ R-/- mouse model after

TABLE 5. Infectious agents and TA

Infectious agent	Frequency of association	Supporting data
<i>Mycobacterium tuberculosis</i>	Possible [110]	Laboratory tests and anecdotal cases
<i>Chlamydia pneumoniae</i>	Possible [111, 112]	Experimental
RNA virus	Possible [113, 114]	Experimental
Herpes virus	Possible [113, 114]	Experimental
CMV	Possible [115, 116]	Experimental

TABLE 6. Infectious agents and GCA

Infectious agent	Frequency of association	Supporting data
<i>Chlamydia pneumoniae</i>	Possible [9, 119–121]	Serological
Parvovirus B19	Possible [9, 119–121]	Serological
Parainfluenza virus	Possible [9, 119–121]	Serological

infection with a γ -herpes virus, suggesting that IFN- γ plays an important role in virus-induced vasculitides [10] (Table 5).

Recent studies revealed a significant correlation between mHSP65 and hHSP60 reactive T cells as well as anti-mHSP65 and anti-hHSP60 IgG antibodies, suggesting an infection-induced autoimmunity in this disease, related to a potential molecular mimicry between mHSP65 and hHSP60 [117].

GCA

In GCA, vasculitis is mainly a T-cell driven process triggered by exposure to antigens (probably infectious). The sudden onset and variation in incidence between different geographical regions has led to the hypothesis that there is a genetic predisposition, correlated with environmental factors including infection, in this vasculitis. Infectious triggers have been searched for at the biological and epidemiological level. The pre-existence of clinical infections has been suggested in GCA, but without any epidemiological support, even though simultaneous peaks of GCA/PMR and respiratory infections have been reported [118].

Candidate pathogens in GCA, such as *C. pneumoniae*, parvovirus B19 and parainfluenza virus have been identified by PCR techniques [9, 119, 120] and/or serological tests [121].

For some authors, it seems that only reinfection with *Chlamydia* may induce vasculitis [122], but these data were not confirmed.

Various pathogens have been anecdotally reported in GCA including VZV, EBV, CMV, *C. psittaci*, *Borrelia burgdorferi* and *Treponema pallidum*, but without any serological or epidemiological basis (Table 6).

Behçet's disease

Behçet's disease is a chronic vasculitis of unknown aetiology. However, both viral and bacterial infections have been suspected to be involved in the pathogenesis of this disease [123]. *Streptococcus* species are suggested to play an important role in Behçet's disease. Stimulation with streptococcal antigens, as assessed by RT-PCR and ELISA, specifically increased expression of IL-12 p40 mRNA and protein, in conjunction with IL-12 p70 induction, in peripheral blood mononuclear cells from Behçet's disease patients [124].

Oral *Streptococcus* infections are classically reported in this form of vasculitis, but other pathogens have also been occasionally found (Table 7).

However, recently, parvovirus B19 DNA has been detected in the cutaneous lesions of patients with Behçet's disease [135]. Further progress in this field is being made using animal models of infection. For instance, Sohn *et al.* [136] has reported Behçet-like symptoms in ICR mice induced by HSV infection. However, recently, the same authors further suggest that viral infection

TABLE 7. Infectious agents and Behçet's disease

Infectious agent	Frequency of association	Supporting data
<i>Streptococcus</i>	Possible [123, 124]	Laboratory data
<i>Staphylococcus aureus</i>	Weak [125]	Anecdotal cases
<i>Borrelia burgdorferi</i>	Weak [126]	Anecdotal cases
<i>Nocardia</i>	Weak [127]	Anecdotal cases
<i>Helicobacter pylori</i>	Weak [128]	Anecdotal cases
<i>Yersinia</i>	Weak [129]	Anecdotal cases
<i>Campylobacter</i>	Weak [129]	Anecdotal cases
<i>Salmonella</i>	Weak [129]	Anecdotal cases
<i>Chlamydia</i>	Weak [129]	Anecdotal cases
HSV	Possible [130]	Experimental and anecdotal cases
Parvovirus B19	Possible [131, 135]	Case series and anecdotal cases
HAV	Weak [132]	Anecdotal cases
HBV	Weak [132]	Anecdotal cases
HCV	Weak [132]	Anecdotal cases
HEV	Weak [132]	Anecdotal cases
HIV	Weak [133]	Anecdotal cases
EBV	Weak [134]	Anecdotal cases

alone is not sufficient to induce Behçet's disease, and that immunological abnormalities are necessary [137].

Cogan's syndrome

Chlamydia species have been reported in Cogan's syndrome. In fact, five cases of vasculitis with serological findings indicating *C. pneumoniae* infection were reported by Ljungstrom *et al.* [138]. There are, however, no prevalence or microbiological studies, and no animal models that could support the correlation between Cogan disease and infection.

Vasculitis related to drugs

A large number of drugs, particularly antibiotics (β -lactams), can induce vasculitis which is mainly cutaneous. The incidence of antibiotic-induced vasculitis is probably underestimated, but drug-induced vasculitides are encountered more frequently than those secondary to infections. Among the drugs most frequently implicated have been sulphonamides, penicillin, allopurinol, thiazides, hydantoins, aspirin and propylthiouracil [139, 140]. Penicillin causes vasculitis by conjugating to serum proteins and mediating immune complex vasculitis as in type III hypersensitivity reactions [141].

Therapeutic agents from virtually every pharmacological class have been implicated in the development of drug-induced vasculitis [139, 140] and the mechanisms involved are mainly related to immune complex arterial deposits with antigen excess.

Drugs such as propylthiouracil and hydralazine appear to induce antibody production, specifically ANCA, although a clear cut causal relationship has not yet been proved [142].

The clinical spectrum of drug-induced vasculitis consists mainly of leucocytoclastic and hypersensitivity vasculitis, rarely necrotizing vasculitides, PAN-like, Churg–Strauss syndrome or cerebral vasculitis [143, 144]. Withdrawal of the drug is often followed by prompt resolution of clinical manifestations. However, some severe cases require corticosteroids, plasmapheresis, haemodialysis or cyclophosphamide, and death is reported in ~10% of the cases despite treatment. Sometimes systemic small-sized vessel vasculitis is described after massive antigen inhalation [145].

Several studies in animal models have shown that inhalation of soluble proteins through the respiratory tract leads to activation of CD4⁺ 'helper' T cells. Exposure to aerosolized antigen appears to favour the generation of Th2 cells that secrete cytokines, predominantly IL-4, -5 and -13, which support the induction of humoral immunity [146].

Other authors have also identified a role for CD8⁺ T cells after exposure to aerosolized proteins and these have been implicated in

the control of airway hyperresponsiveness (AHR) through their capacity to secrete IFN [147].

Using scanning electron microscopy, Fischer *et al.* [148] and Moore *et al.* [149] have reported epithelial shedding and accumulation of inflammatory cells, expected signs of allergic airway inflammation, following inhalation of aerosolized antigen by immunized guinea pigs.

Anti-TNF treatments, even though a promising therapy for vasculitis, can sometimes induce a number of adverse effects, including vasculitis [150].

Therefore, recently, 39 cases of vasculitis during anti-TNF- α therapy were identified among 1200 French patients receiving this treatment [151].

A larger cohort of patients with autoimmune diseases has been reported between January 1990 and December 2006 after anti-TNF- α therapy by Ramos-Casals *et al.* [152] (233 cases, and among them 113 with vasculitis). Interestingly, in 25% of the cases the vasculitis had a systemic presentation, and in most of the situations the prognosis was poor, in spite of cessation of anti-TNF treatment [152].

Furthermore, due to their interference with the patient's immune system, anti-TNF and/or infliximab treatments are followed by an increased incidence of opportunistic infections, particularly tuberculosis [153], but also *Salmonella* and/or *Listeria* infections [154]. Other new therapies such as INF- α -2b also induce vasculitis [155].

Conclusion

The link between infection and vasculitis is an intriguing subject that has not yet been explored thoroughly. Vasculitis is associated with infections, immunization and anti-microbial drugs, and infections are reported during vasculitides and are presumed to be trigger factors. There are situations where one pathogen could be responsible for various types of vasculitis (e.g. HIV) and, conversely, where several micro-organisms could induce the same vasculitic syndrome (PAN).

However, in most of these instances, data come from only a few sporadic case reports and a firm conclusion linking the infectious agent to the pathogenesis of vasculitis cannot be drawn. A causal relationship between infection and vasculitis has been proven in only few situations (HBV and HCV in PAN and cryoglobulinaemia, respectively). The physiopathology of the complex relationship between infection and vasculitis is not understood completely, but new molecular tools should allow a better understanding of the mechanisms underlying these pathologies and may offer a different therapeutic approach in the future.

Rheumatology key messages

- Infections are responsible for different types of vasculitis, but in most cases this link remains hypothetical.
- A causal relationship has only been established in few instances (PAN, HBV, cryoglobulinaemia and HCV).
- Several mechanisms could be involved in primary vasculitis related to infections.

Acknowledgement

The authors are most grateful to Richard Medeiros, Medical Editor, Rouen University Hospital.

Disclosure statement: The authors have declared no conflicts of interest.

References

- 1 Pleister A, Eckels DD. Cryptic infection and autoimmunity. *Autoimmun Rev* 2003;2: 126–32.

- 2 Huugen D, Xiao H, van Esch A. Aggravation of anti-myeloperoxidase antibody-induced glomerulonephritis by bacterial lipopolysaccharide: role of tumor necrosis factor- α . *Am J Pathol* 2005;167:47–58.
- 3 Buonocore S, Flamand V, Claessen N, Heeringa P, Goldman M, Florquin S. Dendritic cells overexpressing Fas-ligand induce pulmonary vasculitis in mice. *Clin Exp Immunol* 2004;137:74–80.
- 4 Mathieson PW, Qasim FJ, Esnault VL, Oliveira DB. Animal models of systemic vasculitis. *J Autoimmun* 1993;6:251–64.
- 5 Yamaguchi N, Macdonald DW. Detection of Aleutian disease antibodies in feral American mink in southern England. *Vet Rec* 2001;149:485–8.
- 6 Abe Y, Nakano S, Aita K, Sagishima M. Streptococcal and staphylococcal superantigen-induced lymphocytic arteritis in a local type experimental model: comparison with acute vasculitis in the Arthus reaction. *J Lab Clin Med* 1998;131:93–102.
- 7 Laitinen K, Laurila A, Pyhala L, Leinonen M, Saikku P. Chlamydia pneumoniae infection induces inflammatory changes in the aortas of rabbits. *Infect Immun* 1997;65:4832–5.
- 8 Sohn S, Lee ES, Lee S. The correlation of MHC haplotype and development of Behçet's disease-like symptoms induced by herpes simplex virus in several inbred mouse strains. *J Dermatol Sci* 2001;26:173–81.
- 9 Sohn S, Lee ES, Bang D, Lee S. Behçet's disease-like symptoms induced by the herpes simplex virus in the ICR mice. *Eur J Dermatol* 1998;8:21–3.
- 10 Weck KE. Murine gamma-herpesvirus 68 causes severe large-vessel arteritis in mice lacking interferon-gamma responsiveness: a new model for virus-induced vascular disease. *Nat Med* 1997;3:1346–53.
- 11 Paessler S, Aguilar P, Anishchenko M. The hamster as an animal model for eastern equine encephalitis and its use in studies of virus entrance into the brain. *J Infect Dis* 2004;189:2072–6.
- 12 Guillevin L. Virus-induced systemic vasculitides: new therapeutic approaches. *Clin Dev Immunol* 2004;11:227–31.
- 13 Pagnoux C, Cohen P, Guillevin L. Vasculitides secondary to infections. *Clin Exp Rheumatol* 2006;24:S71–81.
- 14 Millikan LE, Flynn TC. Infectious etiologies of cutaneous vasculitis. *Clin Dermatol* 1999;17:509–14.
- 15 Witort-Serraglini E, Del Rosso M, Lotti TM *et al.* Endothelial injuries in vasculitides. *Clin Dermatol* 1999;17:587–90.
- 16 Tervaert JWC, Popa ER, Bos NA. The role of superantigens in vasculitis. *Curr Opin Rheum* 1999;11:24–33.
- 17 Dimitrakopoulos AN, Kordossis T, Hatzakis A, Moutsopoulos HM. Mixed cryoglobulinemia in HIV-1 infection: the role of HIV-1. *Ann Intern Med* 1999;130:226–30.
- 18 Kordossis T, Sipsas NV, Kontos A, Dafni U, Moutsopoulos HM. Mixed cryoglobulinemia is associated with increased risk for death, or neoplasia in HIV-1 infection. *Eur J Clin Invest* 2001;31:1078–82.
- 19 Fabris P, Tositti G, Giordani MT. Prevalence and clinical significance of circulating cryoglobulins in HIV-positive patients with and without co-infection with hepatitis C virus. *J Med Virol* 2003;69:339–43.
- 20 Saadoun D, Aaron L, Resche-Rigon M, Pialoux G, Piette JC, Cacoub P; GERMIVIC Study Group. Cryoglobulinaemia vasculitis in patients coinfecting with HIV and hepatitis C virus. *AIDS* 2006;20:871–7.
- 21 Ramos-Casals M, Forns X, Brito-Zerón P. Cryoglobulinaemia associated with hepatitis C virus: influence of HCV genotypes, HCV-RNA viraemia and HIV coinfection. *J Viral Hepat* 2007;14:736–42.
- 22 Aaron L, Lebray P, Alyanikian MA. Prevalence of mixed cryoglobulins in relation to CD4 cell count among patients coinfecting with HIV and hepatitis C virus. *Clin Infect Dis* 2005;40:306–8.
- 23 Weyand CM, Goronzy JJ. Medium- and large-vessel vasculitis. *N Engl J Med* 2003;349:160–9.
- 24 Mandes ST. Toxin-mediated streptococcal and staphylococcal disease. *J Am Acad Dermatol* 1998;39:383–98.
- 25 Gocke DJ, Hsu K, Morgan C, Bombardieri S, Lockshin M, Christian CL. Association between polyarteritis and Australia antigen. *Lancet* 1970;2:1149–53.
- 26 Trepo C, Guillevin L. Polyarteritis nodosa and extrahepatic manifestations of HBV infection: the case against autoimmune intervention in pathogenesis. *J Autoimmun* 2001;16:269–74.
- 27 Gayraud M, Guillevin L, le Toumelin P *et al.*; French Vasculitis Study Group. Long-term follow up of polyarteritis nodosa, microscopic polyangiitis, and Churg-Strauss syndrome: analysis of four prospective trials including 278 patients. *Arthritis Rheum* 2001;44:666–75.
- 28 Guillevin L, Lhote F, Leon A, Fauvelle F, Vivitski L, Trepo C. Treatment of polyarteritis nodosa related to hepatitis B virus with short term steroid therapy associated with antiviral agents and plasma exchanges. A prospective trial in 33 patients. *J Rheumatol* 1993;20:289–98.
- 29 Guillevin L, Lhote F, Jarrousse B, Fain O. Treatment of polyarteritis nodosa and Churg-Strauss syndrome. A meta-analysis of 3 prospective controlled trials including 182 patients over 12 years. *Ann Med Interne* 1992;143:405–16.
- 30 Quint L, Deny P, Guillevin L. Hepatitis C virus in patients with polyarteritis nodosa. Prevalence in 38 patients. *Clin Exp Rheumatol* 1991;9:253–7.
- 31 Guillevin L, Mahr A, Callard P *et al.*; French Vasculitis Study Group. Hepatitis B virus-associated polyarteritis nodosa: clinical characteristics, outcome, and impact of treatment in 115 patients. *Medicine* 2005;84:313–22.
- 32 Cacoub P, Maisonobe T, Thibault V *et al.* Systemic vasculitis in patients with hepatitis C. *Rheumatology* 2001;28:109–18.
- 33 Tonnelier JM, Ansart S, Tilly-Gentric A, Pennec YL. Juvenile relapsing periarteritis nodosa and streptococcal infection. *Joint Bone Spine* 2000;67:346–8.
- 34 David J, Ansell BM, Woo P. Polyarteritis nodosa associated with streptococcus. *Arch Dis Child* 1993;69:685–8.
- 35 Fink CW. The role of the streptococcus in poststreptococcal reactive arthritis and childhood polyarteritis nodosa. *J Rheumatol* 1991;29:14–20.
- 36 Smail A, Ducroix JP, Tondriaux A, Sevestre H, Yzet T, Baillet J. The role of infection in the precipitation of periarteritis nodosa. *Ann Med Interne* 1988;139:324–30.
- 37 Pile K, Kwong T, Fryer J, Laurent R. Polyarteritis associated with *Yersinia enterocolitica* infection. *Ann Rheum Dis* 1992;51:678–80.
- 38 Chiche L, Jean R, Cretel E, Figuerella-Branger D, Durand JM. Central nervous system HIV-associated polyarteritis nodosa: long-term outcome. *Rev Med Interne* 2006;27:625–8.
- 39 Deeren DH, De Backer AI, Malbrain ML, Verbraeken H, Blockmans D. Treatment of hepatitis B virus-related polyarteritis nodosa: two case reports and a review of the literature. *Clin Rheumatol* 2004;23:172–6.
- 40 Garcia-Garcia JA, Macias J, Castellanos V *et al.* Necrotizing granulomatous vasculitis in advanced HIV infection. *J Infect* 2003;47:333–5.
- 41 Durst R, Goldschmidt N, Ben Yehuda A. Parvovirus B19 infection associated with myelosuppression and cutaneous polyarteritis nodosa. *Rheumatology* 2002;41:1210–2.
- 42 Viguier M, Guillevin L, Laroche L. Treatment of parvovirus B19-associated polyarteritis nodosa with intravenous immune globulin. *N Engl J Med* 2001;344:1481–2.
- 43 Cohen P, Guillevin L. Vasculitis associated with viral infections. *Presse Med* 2004;33:1371–84.
- 44 Peng SL. Rheumatic manifestations of parasitic diseases. *Semin Arthritis Rheum* 2002;31:228–47.
- 45 McGill PE. Rheumatic syndromes associated with parasites. *Baillieres Clin Rheumatol* 1995;9:201–13.
- 46 Frayha RA. Trichinosis-related polyarteritis nodosa. *Am J Med* 1981;71:307–12.
- 47 Guillevin L, Jarrousse B, Lok C *et al.* Longterm follow up after treatment of polyarteritis nodosa and Churg-Strauss angitis with comparison of steroids, plasma exchange and cyclophosphamide to steroids and plasma exchange. A prospective randomized trial of 71 patients. The Cooperative Study Group for Polyarteritis Nodosa. *J Rheumatol* 1991;18:567–74.
- 48 Guillevin L, Cohen P, Mahr A *et al.* Treatment of polyarteritis nodosa and microscopic polyangiitis with poor prognosis factors: a prospective trial comparing glucocorticoids and six or twelve cyclophosphamide pulses in sixty-five patients. *Arthritis Rheum* 2003;49:93–100.
- 49 Guillevin L, Mahr A, Cohen P *et al.*; French Vasculitis Study Group. Short-term corticosteroids then lamivudine and plasma exchanges to treat hepatitis B virus-related polyarteritis nodosa. *Arthritis Rheum* 2004;51:482–7.
- 50 Misiani R, Bellavita P, Fenili D *et al.* Hepatitis C virus infection in patients with essential mixed cryoglobulinemia. *Ann Intern Med* 1992;117:573–7.
- 51 Wong VX, Egner W, Eisey T, Brown D, Alexander GJ. Incidence, character and clinical relevance of mixed cryoglobulinemia in patients with chronic hepatitis C virus infection. *Clin Exp Immunol* 1996;104:25–31.
- 52 Sansonno D, Lauletta G, Montrone M, Tucci FA, Nisi L, Dammacco F. Virological analysis and phenotypic characterization of peripheral blood lymphocytes of hepatitis C virus-infected patients with and without mixed cryoglobulinemia. *Clin Exp Immunol* 2006;143:288–96.
- 53 Horcajada JP, Garcia-Bengochea M, Cilla G, Etxaniz P, Cuadrado E, Arenas JI. Mixed cryoglobulinemia in patients with chronic hepatitis C infection: prevalence, significance and relationship with different viral genotypes. *Ann Med* 1999;31:352–8.
- 54 Levo Y, Gorevic PD, Kassab HJ, Zucker-Franklin D, Franklin EC. Association between hepatitis B virus and essential mixed cryoglobulinemia. *N Engl J Med* 1977;296:1501–4.
- 55 Levo Y. Hepatitis B virus and essential mixed cryoglobulinemia. *Ann Intern Med* 1981;94:282.
- 56 Garcia de La Pena Lefebvre P, Mouthon L, Cohen P, Lhote F, Guillevin L. Polyarteritis nodosa and mixed cryoglobulinemia related to hepatitis B and C virus coinfection. *Ann Rheum Dis* 2001;60:1068–9.
- 57 Christodoulou DK, Dalekos GN, Merkouropoulos MH *et al.* Cryoglobulinemia due to chronic viral hepatitis infections is not a major problem in clinical practice. *Eur J Int Med* 2001;12:435–41.
- 58 Horowitz J, Klein M, Sukenik S. Cryoglobulinemia and hepatitis B markers in North African Jews with Raynaud's disease. *Arthritis Rheum* 1986;29:1026–8.
- 59 Delannoy D, Balquet MH, Savinel P. Vasculitis with mixed cryoglobulin in human parvovirus B19 infection. *Presse Med* 1993;22:175.
- 60 Fabris P, Tositti G, Giordani MT *et al.* Prevalence and clinical significance of circulating cryoglobulins in HIV-positive patients with and without co-infection with hepatitis C virus. *J Med Virol* 2003;69:339–43.
- 61 Kramer J, Hennig H, Lensing C *et al.* Multi-organ affecting CMV-associated cryoglobulinemic vasculitis. *Clin Nephrol* 2006;66:284–90.
- 62 Takeuchi T, Yoshioka K, Hori A, Mukoyama K, Ohsawa A, Yokoh S. Cytomegalovirus mononucleosis with mixed cryoglobulinemia presenting transient pseudothrombocytopenia. *Intern Med* 1993;32:598–601.
- 63 Fiorini G, Bernasconi P, Sinico RA, Chianese R, Pozzi F, D'Amico G. Increased frequency of antibodies to ubiquitous viruses in essential mixed cryoglobulinemia. *Clin Exp Immunol* 1986;64:65–70.
- 64 Fiorini GF, Sinico RA, Winearls C, Custode P, De Giuli-Morghen C, D'Amico G. Persistent Epstein-Barr virus infection in patients with type II essential mixed cryoglobulinemia. *Clin Immunol Immunopathol* 1988;47:262–9.
- 65 Cacoub P, Boukli N, Hausfater P *et al.* Parvovirus B19 infection, hepatitis C virus infection, and mixed cryoglobulinemia. *Ann Rheum Dis* 1998;57:422–4.
- 66 Misiani R, Bellavita P, Fenili D *et al.* Interferon alpha-2a therapy in cryoglobulinemia associated with hepatitis C virus. *N Engl J Med* 1994;330:751–6.
- 67 Saadoun D, Resche-Rigon M, Thibault V, Piette JC, Cacoub P. Antiviral therapy for hepatitis C virus-associated mixed cryoglobulinemia vasculitis: a long-term followup study. *Arthritis Rheum* 2006;54:3696–706.

- 68 Cacoub P, Delluc A, Saadoun D, Landau DA, Sene D. Anti-CD20 monoclonal antibody (rituximab) treatment for cryoglobulinemia vasculitis: where do we stand? *Ann Rheum Dis* 2008;67:283–7.
- 69 Fan PT, Davis JA, Somer T, Kaplan L, Bluestone R. A clinical approach to systemic vasculitis. *Semin Arthritis Rheum* 1980;9:248–304.
- 70 Hoffman GS. Wegener granulomatosis. *Curr Opin Rheumatol* 1993;5:11–7.
- 71 Stegeman CA, Tervaert JW, Sluiter WJ, Manson WL, de Jong PE, Kallenberg CG. Association of chronic nasal carriage of *Staphylococcus aureus* and higher relapse rates in Wegener granulomatosis. *Ann Intern Med* 1994;120:12–7.
- 72 Popa ER, Tervaert JW. The relation between *Staphylococcus aureus* and Wegener's granulomatosis: current knowledge and future directions. *Intern Med* 2003;42:771–80.
- 73 DeRemee RA, McDonald TJ, Weiland LH. Wegener's granulomatosis: observations on treatment with antimicrobial agents. *Mayo Clin Proc* 1985;60:27–32.
- 74 Brons RH, Bakker HI, Van Wijk RT *et al*. *Staphylococcal acid phosphatase binds to endothelial cells via charge interaction; a pathogenic role in Wegener's granulomatosis?* *Clin Exp Immunol* 2000;119:566–7.
- 75 Popa ER, Stegeman CA, Bos NA, Kallenberg CG, Tervaert JW. *Staphylococcal superantigens and T cell expansions in Wegener's granulomatosis.* *Clin Exp Immunol* 2003;132:496–504.
- 76 Nikkari S, Mertsola J, Korvenranta H, Vainionpää R, Toivanen P. Wegener's granulomatosis and parvovirus B19 infection. *Arthritis Rheum* 1994;37:1707–8.
- 77 Finkel TH, Török TJ, Ferguson PJ *et al*. Chronic parvovirus B19 infection and systemic necrotising vasculitis: opportunistic infection or aetiological agent? *Lancet* 1994;343:1255–8.
- 78 Gibb W, Williams A. Nocardiosis mimicking Wegener's granulomatosis. *Scand J Infect Dis* 1986;18:583–5.
- 79 Okano M, Thiele GM, Sakiyama Y, Matsumoto S, Purtilo DT. Adenovirus infection in patients with Kawasaki disease. *J Med Virol* 1990;32:53–7.
- 80 Shingadia D, Bose A, Booy R. Could a herpesvirus be the cause of Kawasaki disease? *Lancet Infect Dis* 2002;2:310–3.
- 81 Leen C, Ling S. Mycoplasma infection and Kawasaki disease. *Arch Dis Child* 1996;75:266–7.
- 82 Akiyama T, Yashiro K. Probable role of *Streptococcus pyogenes* in Kawasaki disease. *Eur J Pediatr* 1993;152:82–92.
- 83 Morita A, Imada Y, Igarashi H, Yutsudo T. Serologic evidence that streptococcal superantigens are not involved in the pathogenesis of Kawasaki disease. *Microbiol Immunol* 1997;41:895–900.
- 84 Leung DY, Meissner HC, Fulton DR, Murray DL, Kotzin BL, Schlievert PM. Toxic shock syndrome toxin-secreting *Staphylococcus aureus* in Kawasaki syndrome. *Lancet* 1993;342:1385–8.
- 85 Terai M, Miwa K, Williams T *et al*. The absence of evidence of staphylococcal toxin involvement in the pathogenesis of Kawasaki disease. *J Infect Dis* 1995;172:558–61.
- 86 Kato H, Fujimoto T, Inoue O *et al*. Variant strain of *Propionibacterium acnes*: a clue to the etiology of Kawasaki disease. *Lancet* 1983;2:1383–8.
- 87 Edlinger EA, Benichou J, Labruno B. Positive Ehrlichia canis serology in Kawasaki disease. *Lancet* 1980;1:1146–7.
- 88 Rathore MH, Barton LL, Dawson JE, Regnery RL, Ayoub EM. Ehrlichia chaffeensis and Rochalimaea antibodies in Kawasaki disease. *J Clin Microbiol* 1993;31:3058–9.
- 89 Carter RF, Haynes ME, Morton J. Rickettsia-like bodies and splenitis in Kawasaki disease. *Lancet* 1976;2:1254–5.
- 90 Shishido A. Failure to confirm the rickettsial etiology of MCLS (Kawasaki disease). *Jpn J Med Sci Biol* 1979;32:250–1.
- 91 Muso E, Fujiwara H, Yoshida R *et al*. Epstein-Barr virus genome-positive tubulointerstitial nephritis associated with Kawasaki disease-like coronary aneurysms. *Clin Nephrol* 1993;40:7–15.
- 92 Culora GA, Moore IE. Kawasaki disease, Epstein-Barr virus and coronary artery aneurysms. *J Clin Pathol* 1997;50:161–3.
- 93 Shulman ST, Rowley AH, Fresco R, Morrison DC. The etiology of Kawasaki disease: retrovirus? *Prog Clin Biol Res* 1987;250:117–24.
- 94 Burns JC, Geha RS, Schneeberger EE *et al*. Polymerase activity in lymphocyte culture supernatants from patients with Kawasaki disease. *Nature* 1986;323:814–6.
- 95 Esper F, Shapiro ED, Weibel C, Ferguson D, Landry ML, Kahn JS. Association between a novel human coronavirus and Kawasaki disease. *J Infect Dis* 2005;191:499–502.
- 96 Schulz F, Hoad JG, Whitby D, Tizard EJ, Dillon MJ, Weiss RA. A measles virus isolate from a child with Kawasaki disease: sequence comparison with contemporaneous isolates from 'classical' cases. *J Gen Virol* 1992;73:1581–6.
- 97 Whitby D, Hoad JG, Tizard EJ *et al*. Isolation of measles virus from child with Kawasaki disease. *Lancet* 1991;338:1215.
- 98 Normann E, Naas J, Gnarpe JH, Backman H, Gnarpe H. Demonstration of Chlamydia pneumoniae in cardiovascular tissues from children with Kawasaki disease. *Pediatr Infect Dis J* 1999;18:72–3.
- 99 Strigl S, Kuttlin A, Roblin PM, Shulman S, Hammerschlag MR. Is there an association between Kawasaki disease and Chlamydia pneumoniae? *J Infect Dis* 2000;181:2103–5.
- 100 Hammerschlag MR, Boman J, Rowley AH. Failure to demonstrate Chlamydia pneumoniae in cardiovascular tissue from children with Kawasaki disease. *Pediatr Infect Dis J* 2001;20:76–7.
- 101 Swaby ED, Fisher-Hoch S, Lambert HP, Stern H. Is Kawasaki disease a variant of Q fever? *Lancet* 1980;2:146.
- 102 Weir WR, Bouchet VA, Milford E, Taylor RF, Smith H. Kawasaki disease in European adult associated with serological response to *Coxiella burnetii*. *Lancet* 1985;2:504.
- 103 Lehman TJ, Warren R, Gietl D, Mahnovski V, Prescott M. Variable expression of *Lactobacillus casei* cell wall-induced coronary arteritis: an animal model of Kawasaki's disease in selected inbred mouse strains. *Clin Immunol Immunopathol* 1988;48:108–18.
- 104 Nagi-Miura N, Shingo Y, Adachi Y *et al*. Induction of coronary arteritis with administration of CAWS (Candida albicans water-soluble fraction) depending on mouse strains. *Immunopharmacol Immunotoxicol* 2004;26:527–43.
- 105 Curtis N, Zheng R, Lamb JR, Levin M. Evidence for a superantigen mediated process in Kawasaki disease. *Arch Dis Child* 1995;72:308–11.
- 106 Mancia L, Wahlstrom J, Schiller B *et al*. Characterization of the T-cell receptor V-beta repertoire in Kawasaki disease. *Scand J Immunol* 1998;48:443–9.
- 107 Duong TT, Silverman ED, Bissessar MV, Yeung RS. Superantigen activity is responsible for induction of coronary arteritis in mice: an animal model of Kawasaki disease. *Int Immunol* 2003;15:79–89.
- 108 Hui-Yuen JS, Duong TT, Yeung RS. TNF-alpha is necessary for induction of coronary artery inflammation and aneurysm formation in an animal model of Kawasaki disease. *J Immunol* 2006;176:6294–301.
- 109 Meissner HC, Leung DY. Superantigens, conventional antigens and the etiology of Kawasaki syndrome. *Pediatr Infect Dis J* 2000;19:91–4.
- 110 Aggarwal A, Chag M, Sinha N, Naik S. Takayasu's arteritis: role of Mycobacterium tuberculosis and its 65 kDa heat shock protein. *Int J Cardiol* 1996;55:49–55.
- 111 Fong IW, Chiu B, Viira E, Fong MW, Jang D, Mahony J. Rabbit model for Chlamydia pneumoniae infection. *J Clin Microbiol* 1997;35:48–52.
- 112 Laitinen K, Laurila A, Pyhäälä L, Leinonen M, Saikku P. Chlamydia pneumoniae infection induces inflammatory changes in the aortas of rabbits. *Infect Immun* 1997;65:4832–5.
- 113 Rossow KD, Bautista EM, Goyal SM *et al*. Experimental porcine reproductive and respiratory syndrome virus infection in one-, four-, and 10-week-old pigs. *J Vet Diagn Invest* 1994;6:3–12.
- 114 Cooper VL, Hesse RA, Doster AR. Renal lesions associated with experimental porcine reproductive and respiratory syndrome virus (PRRSV) infection. *J Vet Diagn Invest* 1997;9:198–201.
- 115 Berencsi K, Endresz V, Klurfeld D, Kari L, Kritchevsky D, Gönczöl E. Early atherosclerotic plaques in the aorta following cytomegalovirus infection of mice. *Cell Adhes Commun* 1998;5:39–47.
- 116 Presti RM, Pollock JL, Dal Canto AJ, O'Guin AK, Virgin HW. Interferon gamma regulates acute and latent murine cytomegalovirus infection and chronic disease of the great vessels. *J Exp Med* 1998;18:577–88.
- 117 Kumar Chauhan S, Kumar Tripathy N, Sinha N, Singh M, Nityanand S. Cellular and humoral immune responses to mycobacterial heat shock protein-65 and its human homologue in Takayasu's arteritis. *Clin Exp Immunol* 2004;138:547–53.
- 118 Elling P, Olsson AT, Elling H. Synchronous variations of the incidence of temporal arteritis and polymyalgia rheumatica in different regions of Denmark; association with epidemics of Mycoplasma pneumoniae infection. *J Rheumatol* 1996;23:112–9.
- 119 Gordon LK, Goldman M, Sandusky H *et al*. Identification of candidate microbial sequences from inflammatory lesion of giant cell arteritis. *Clin Immunol* 2004;111:286–96.
- 120 Wagner AD, Gerard HC, Freseman T *et al*. Detection of Chlamydia pneumoniae in giant cell vasculitis and correlation with the topographic arrangement of tissue-infiltrating dendritic cells. *Arthritis Rheum* 2000;43:1543–51.
- 121 Duhaut P, Bosshard S, Calvet A *et al*. Giant cell arteritis, polymyalgia rheumatica, and viral hypotheses: a multicenter, prospective case-control study. Groupe de Recherche sur l'Artérite à Cellules Géantes. *J Rheumatol* 1999;26:361–9.
- 122 Ljungstrom L, Franzen C, Schlaug M, Elowson S, Viidas U. Reinfection with Chlamydia pneumoniae may induce isolated and systemic vasculitis in small and large vessels. *Scand J Infect Dis Suppl* 1997;104:37–40.
- 123 Lehner T. The role of heat shock protein, microbial and autoimmune agents in the aetiology of Behcet's disease. *Int Rev Immunol* 1997;14:21–32.
- 124 Yanagihori H, Oyama N, Nakamura K, Mizuki N, Oguma K, Kaneko F. Role of IL-12B promoter polymorphism in Adamantiades-Behcet's disease susceptibility: an involvement of Th1 immunoreactivity against Streptococcus sanguinis antigen. *J Invest Dermatol* 2006;126:1534–40.
- 125 Suga Y, Tsuboi R, Kobayashi S, Ogawa H. A case of Behcet's disease aggravated by gingival infection with methicillin-resistant Staphylococcus aureus. *Br J Dermatol* 1995;133:319–21.
- 126 Onen F, Tuncer D, Akar S, Birlik M, Akkoc N. Seroprevalence of Borrelia burgdorferi in patients with Behcet's disease. *Rheumatol Int* 2003;23:289–93.
- 127 Pamuk GE, Pamuk ON, Tabak F, Mert A, Ozturk R, Aktuglu Y. Systemic Nocardia infection in a patient with Behcet's disease. *Rheumatology* 2001;40:597–9.
- 128 Avci O, Ellidokuz E, Simsek I, Buyukgebiz B, Gunes AT. Helicobacter pylori and Behcet's disease. *Dermatology* 1999;199:140–3.
- 129 Toivanen A, Lahesmaa-Rantala R, Meurman O *et al*. Antibodies against Yersinia, Campylobacter, Salmonella, and Chlamydia in patients with Behcet's disease. *Arthritis Rheum* 1987;30:1315–7.
- 130 Tojo M, Zheng X, Yanagihori H *et al*. Detection of herpes virus genomes in skin lesions from patients with Behcet's disease and other related inflammatory diseases. *Acta Derm Venereol* 2003;83:124–7.
- 131 Kiraz S, Ozturk MA, Ertelil I, Calguneri M. Parvovirus B19 infection in Behcet's disease. *Ann Rheum Dis* 2001;60:814–5.
- 132 Aksu K, Kabasakal Y, Sayiner A *et al*. Prevalence of hepatitis A, B, C and E viruses in Behcet's disease. *Rheumatology* 1999;38:1279–81.
- 133 Stein CM, Thomas JE. Behcet's disease associated with HIV infection. *J Rheumatol* 1991;18:1427–8.
- 134 Sun A, Chang JG, Chu CT, Liu BY, Yuan JH, Chiang CP. Preliminary evidence for an association of Epstein-Barr virus with pre-ulcerative oral lesions in patients with recurrent aphthous ulcers or Behcet's disease. *J Oral Pathol Med* 1998;27:168–75.
- 135 Baskan EB, Yilmaz E, Saricaoglu H *et al*. Detection of parvovirus B19 DNA in the lesional skin of patients with Behcet's disease. *Clin Exp Dermatol* 2007;32:186–90.

- 136 Sohn S, Lee ES, Bang D, Lee S. Behçet's disease-like symptoms induced by the herpes simplex virus in ICR mice. *Eur J Dermatol* 1998;8:21–3.
- 137 Sohn S, Lee ES, Kwon HJ, Lee SI, Bang D, Lee S. Expression of Th2 cytokines decreases the development of and improves Behçet's disease-like symptoms induced by herpes simplex virus in mice. *J Infect Dis* 2001;183:1180–6.
- 138 Ljungstrom L, Franzen C, Schlaug M, Elowson S, Viidas U. Reinfection with *Chlamydia pneumoniae* may induce isolated and systemic vasculitis in small and large vessels. *Scand J Infect Dis Suppl* 1997;104:37–40.
- 139 Quiceno GA, Cush JJ. Iatrogenic rheumatic syndromes in the elderly. *Rheum Dis Clin North Am* 2007;33:123–34.
- 140 Wiik A. Clinical and laboratory characteristics of drug-induced vasculitic syndromes. *Arthritis Res Ther* 2005;7:191–2.
- 141 Parker CW. Drug allergy. *N Engl J Med* 1975;292:511–4.
- 142 Dolman KM, Gans ROB, Vervaat TJ *et al.* Vasculitis and antineutrophil cytoplasmic antibodies associated with propylthiouracil therapy. *Lancet* 1993;342:651–2.
- 143 Bhullar N, Folzenlogen DD. Henoch-Schonlein purpura: upper respiratory tract infection or drug induced? *Arch Intern Med* 2002;162:222–3.
- 144 Aloush V, Litinsky I, Caspi D, Elkayam O. Propylthiouracil-induced autoimmune syndromes: two distinct clinical presentations with different course and management. *Semin Arthritis Rheum* 2006;36:4–9.
- 145 Mouthon L, Khaled M, Cohen P, Guillevin L, Mouthon L, Subra JF. Systemic small sized vessel vasculitis after massive antigen inhalation. *Ann Rheum Dis* 2001;60:903–4.
- 146 McMenamin C, Holt PG. The natural immune response to inhaled soluble protein antigens involves major histocompatibility complex (MHC) class I-restricted CD8⁺ T cell-mediated but MHC class II-restricted CD4⁺ T cell-dependent immune deviation resulting in selective suppression of immunoglobulin E production. *J Exp Med* 1993;178:889–99.
- 147 Renz H, Lack G, Saloga J *et al.* Inhibition of IgE production and normalization of airways responsiveness by sensitized CD8 T cells in a mouse model of allergen-induced sensitization. *J Immunol* 1994;152:351–60.
- 148 Fischer A, McGregor GP, Saria A, Philippin B, Kummer W. Induction of tachykinin gene and peptide expression in guinea pig nodose primary afferent neurons by allergic airway inflammation. *J Clin Invest* 1996;98:2284–91.
- 149 Moore KA, Udem BJ, Weinreich D. Antigen inhalation unmasks NK-2 tachykinin receptor-mediated responses in vagal afferents. *Am J Respir Crit Care Med* 2000;161:232–6.
- 150 Guillevin L, Mouthon L. Tumor necrosis factor-alpha blockade and the risk of vasculitis. *J Rheumatol* 2004;31:1885–7.
- 151 Saint Marcoux B, De Bandt M. Vasculitides induced by TNFalpha antagonists: a study in 39 patients in France. *Joint Bone Spine* 2006;73:710–3.
- 152 Ramos-Casals M, Brito-Zerón P, Muñoz S *et al.* Autoimmune diseases induced by TNF-targeted therapies: analysis of 233 cases. *Medicine* 2007;86:242–51.
- 153 Kroesen S, Widmer AF, Tyndall A, Hasler P. Serious bacterial infections in patients with rheumatoid arthritis under anti-TNF-alpha therapy. *Rheumatology* 2003;42:617–21.
- 154 Netea MG, Radstake T, Joosten LA, van der Meer JW, Barrera P, Kullberg BJ. Salmonella septicemia in rheumatoid arthritis patients receiving anti-tumor necrosis factor therapy: association with decreased interferon-gamma production and Toll-like receptor 4 expression. *Arthritis Rheum* 2003;48:1853–7.
- 155 Pinto JM, Marques MS, Correia TE. Lichen planus and leukocytoclastic vasculitis induced by interferon alpha-2b in a subject with HCV-related chronic active hepatitis. *J Eur Acad Dermatol Venereol* 2003;17:193–5.

Clinical Vignette

doi:10.1093/rheumatology/kep029

Advance Access publication 3 March 2009

Peridental mass in a patient with Forestier's/DISH

A 73-year-old man presented with paresthesias and weakness in the upper extremities. No evidence of joint inflammation or neurological deficit of the lower extremities was present. MRI of the cervical spine revealed a soft tissue pannus mass about the dens process impressing on the spinal cord (Fig. 1). Diffuse idiopathic skeletal hyperostosis (DISH), Forestier's disease, with secondary fusion below C2, was found to be the underlying aetiology. While the differential diagnosis of a peridental mass with cystic lesion at the C1–C2 levels includes arachnoid, fibrous, ependymal, teratomatous, perineural and meningeal cysts, peridental masses have also been detected in patients with rheumatic conditions. Patients with RA with dens erosions and subaxial cervical instability, CPPD with dens involvement ('crowned dens') and synovial cysts of the spine have been reported. Very few patients with peridental masses and DISH have been reported, and only in the neurosurgical literature [1]. These masses may develop in such cases due to enhanced mechanical stress at C1–C2 as the only mobile joint, due to fusion below C2 secondary to DISH. Our patient underwent neurosurgical decompression and C1–C2 Harm's fusion, with neurological improvement and disappearance of the peridental mass on repeat MRI.

Disclosure statement: The authors have declared no conflicts of interest.

NINA BOULMAN¹, ITZHAK ROSNER¹, GLEB SLOBODIN¹,
NINA AVSHOVICH¹, JOY FELD¹, ABDEL-RAUF ZEINA²,
MICHAEL ROZENBAUM¹

¹Bnai Zion Medical Center, Rappaport Faculty of Medicine, Haifa and ²Hillel Yafe Medical Center, Hedera, Israel

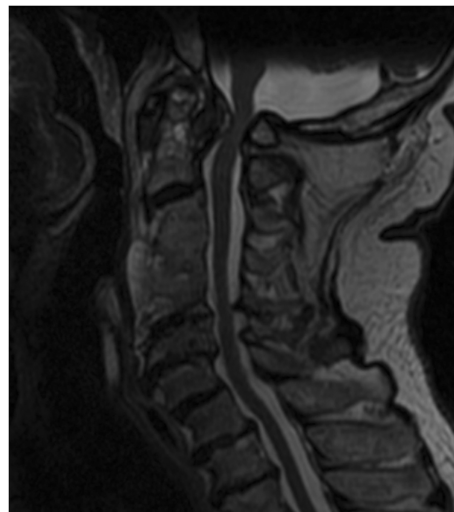


FIG. 1. MR imaging findings in a 73-year-old man with DISH. T2-weighted sagittal MR image shows pannus formation at the craniocervical level and C1–C2 articulation causing severe compression of the medulla oblongata and spinal cord. The hyperintensity within the cord indicates myelopathy. Note the vertebral body fusion at C3–C4–C5 levels.

Correspondence to: Itzhak Rosner.
E-mail: rosneri@tx.technion.ac.il

1 Patel NP, Wright NM, Choi WW, McBride DQ, Johnson JP. Forestier disease associated with a retroodontoid mass causing cervicomedullary compression. *J Neurosurg* 2002;96:190–6.