

Review

Towards a role of ultrasound in children with juvenile idiopathic arthritis

Stefano Lanni^{1,2}, Mark Wood³, Angelo Ravelli^{4,5}, Silvia Magni Manzoni¹, Paul Emery² and Richard J. Wakefield²

Abstract

US is a powerful tool for the assessment of joint synovitis in children with JIA and has been shown to be more accurate than clinical examination in detecting synovial disease. Recent studies have documented the presence of US-detected synovial pathology in children with JIA in clinical remission. US assessment enables the differentiation of joint synovitis from tenosynovitis, may help detect enthesitis and is valuable for capturing cartilage damage and early bone erosions. Guidance to local injection therapy represents an important application of US in routine care. Although US has a great potential for diffusion among paediatric rheumatologists, several issues need to be addressed. In particular, a thorough knowledge of US anatomy of joints in growing children is necessary to interpret US findings in JIA patients. The present review examines the potential role of US in the assessment of joint disease in children with JIA.

Key words: juvenile idiopathic arthritis, synovitis, US, children.

Introduction

The term JIA encompasses a clinically heterogeneous group of disorders characterized by arthritis that begins before 16 years of age, persists for >6 weeks and is of unknown cause [1]. JIA is the most common chronic rheumatic disease in children and is a leading cause of acquired disability in the paediatric age. The ILAR has subclassified the disease entity into seven distinct categories, based on the number of affected joints and the presence of particular extra-articular manifestations [2]. Although the aetiopathogenesis is unclear, the inflammatory process is thought to be of multifactorial origin, and to result from both genetic and environmental factors. The persistence of synovial inflammation may cause cartilage and bone damage and, ultimately, lead to permanent alterations in joint structures and serious impairment of physical function.

In the past decade there have been major advances in the management of JIA, which include the shift towards early aggressive interventions and the development of new therapeutic agents and combination treatment strategies [1, 3]. Reliable documentation of the progress in therapeutic effectiveness makes it important to ensure that the methods used for assessing disease activity are accurate. Currently evaluation of the disease status in children with JIA is based on clinical and laboratory measures. However, these measures have the limitation of not directly measuring inflammation at the primary site of pathology and may be subject to confounding influences. Imaging techniques, such as US and MRI, are capable of directly visualizing and objectively quantifying synovial inflammation and thus represent suitable tools to assess synovitis in children with JIA. These imaging modalities may also enable better and earlier detection of cartilage and bone changes than conventional radiography [4].

US has several advantages over other imaging techniques for use in paediatric subjects, which include non-invasiveness, rapidity of performance, ease of repeatability, high patient acceptability and lack of exposure to ionizing radiation. In addition, it does not require sedation for scanning in younger children. US allows precise and thorough visualization of inflammatory and destructive joint abnormalities, including synovial hyperplasia, joint effusion, cartilage damage, bone erosion, tenosynovitis and enthesopathy [5]. The present review discusses the role of US in the assessment of joint disease in children with JIA.

¹Fondazione Istituto di Ricovero e Cura a Carattere Scientifico Policlinico S. Matteo, Pavia, Italy, ²Academic Department of Musculoskeletal Disease, Chapel Allerton Hospital, ³Department of Paediatric Rheumatology, Leeds Teaching Hospitals NHS Trust, Leeds, UK, ⁴Università degli Studi di Genova and ⁵Istituto Giannina Gaslini, Genova, Italy.

Submitted 4 November 2011; revised version accepted 17 September 2012.

Correspondence to: Richard J. Wakefield, Section of Musculoskeletal Disease, Leeds Institute of Molecular Medicine, 2nd Floor, Chapel Allerton Hospital, Chapeltown Road, Leeds LS7 4SA, UK.
E-mail: medrjw@leeds.ac.uk

Synovitis

US is a powerful tool for the diagnosis and assessment of synovitis. Grey-scale US enables visualization of synovial hyperplasia and joint effusion, whereas the power Doppler (PD) technique is able to demonstrate synovial blood flow. Abnormalities seen with grey-scale US can be residual findings and may not necessarily reflect ongoing active disease [6]. Because PD-US detects synovial blood flow, which is a sign of increased synovial vascularization, it is considered superior to grey-scale US in discriminating between active and inactive disease [7, 8]. PD-US assessment of synovial vascularization has been shown to be more sensitive than serum markers of inflammation in the identification of active disease in JIA [9]. In addition, the degree of vascularity detected by PD-US has been found to be strongly correlated with serum IL-6 levels [10]. However, it has been argued that to consider any PD signal as a sign of synovitis in children during development might be problematic, owing to physiologically enhanced blood flow, which can be misinterpreted as pathological [11].

Recent studies of US in childhood arthritis have used the OMERACT definitions of synovial abnormalities developed for adult patients with inflammatory arthritis [12] to quantify the severity and extent of synovitis. However, these definitions may not be necessarily applicable to paediatric patients, owing to the unique features of the growing skeleton and the changes in joint morphology during development [4]. A thorough knowledge of the US anatomy of joints in growing children is necessary to interpret correctly the presence of synovial inflammation in JIA patients.

Subclinical synovitis

The assessment of joint inflammation in patients with chronic arthritis has been traditionally based on the clinical evaluation of features of joint disease by physicians. However, studies in adult patients with RA as well as in children with JIA have shown that current techniques of clinical examination may underestimate the extent of joint inflammation [13, 14]. Furthermore, histological evidence of synovial pathology has been found in asymptomatic joints [15]. Notably, clinical examination of joints in children with JIA has been found to be poorly reliable [16].

US has been shown to be more accurate than clinical examination in detecting synovitis both in adults with RA [13, 17] and in children with JIA [11, 18–20]. Although not currently included as a component of the new European League Against Rheumatism (EULAR)/ACR RA diagnostic criteria, this ability to detect subclinical disease has been demonstrated to allow earlier fulfilment of the criteria [17]. In 32 children with JIA, Magni-Manzoni *et al.* [18] found that US detects synovitis in many joints recorded as normal on clinical examination. The authors assessed a total of 1664 joints both clinically and with US. A total of 104 (6.3%) and 167 (10%) joints had clinical and US synovitis, respectively. Of the 1560 clinically normal joints, 86 (5.5%) had synovitis on US. The frequency of

subclinical synovitis was greater in wrist, PIP, subtalar and foot joints. US assessment led to reclassification as polyarthritis in five patients who were labelled as having oligoarthritis or were found to have no synovitis on clinical evaluation. Haslam *et al.* [19] also reported a discrepancy between clinical and US examination in the assessment of 17 children with early (<12 months duration) oligoarticular JIA, who had a total of 680 joints evaluated. Six children were found to have subclinical synovitis, with more common involvement of the small joints of hands and feet. One patient was reclassified as having polyarthritis based on US findings. A similar discordance between clinical and US examination in detecting synovitis in peripheral joints in children with JIA has been reported by other investigators [11, 20].

Taken together, these observations suggest that the use of US in children with JIA may allow earlier diagnosis of joint synovitis or of extension of arthritis to clinically normal joints. Furthermore, US findings may have important implications for patient classification and could alter the selection of patients who require the introduction of a second-line or biologic medication or require a change in treatment.

Assessment of disease remission

The current method to assess disease remission in JIA is based on the so-called Wallace criteria [21], which are composed of clinical and laboratory parameters. However, it is unknown whether remission, as defined in the criteria, corresponds to inactive disease as documented by imaging studies. US-detected subclinical synovitis has been shown to be common in adults with RA in clinical remission and to correlate with progression of structural joint damage [6, 22]. Likewise, evidence of ongoing synovial pathology in one or more joints has been documented in a sizeable proportion of patients with JIA classified as having inactive disease on clinical grounds [23, 24]. However, the clinical, significance and prognostic value of this finding is unclear, as the presence of abnormalities on US, including PD signal, did not predict subsequent synovitis flare [24]. This finding contrasts with the observation in adults with RA that vascularization detected by PD-US predicts short-term disease flare after clinical remission [25, 26]. The lack of predictive value of PD signal in JIA has been related to the difficulty to establish whether the presence of juxta-articular flow at PD-US examination in the growing child represents normal flow of the well-vascularized cartilage of the epiphysis or synovial hyperaemia indicating inflammation. Another possible explanation lies in the potential confounding influence of the physiologically enhanced synovial blood flow on the appraisal of low-grade PD signal in growing children [4, 24].

Tenosynovitis

Tendons can be affected throughout the whole course of JIA. In the presence of articular and peri-articular inflammation, it is sometimes difficult to ascertain with clinical

examination whether joint swelling is due to synovitis, tenosynovitis or both. This problem may have a relevant impact on the effectiveness of therapeutic interventions. For example, a poor response to an IA CS (IAC) injection in a complex joint with numerous adjacent tendons, such as the ankle or the wrist, might be explained by the inaccurate identification of the truly affected anatomical structure. Using US, Rooney *et al.* [27] evaluated the prevalence of synovitis and tenosynovitis in 34 JIA patients who had clinically detected swelling in 49 ankles. Only 29% of ankles had tibio-talar effusion alone, whereas tenosynovitis and tenosynovitis alone were detected in 71 and 39% of ankles, respectively. Concomitant tenosynovitis and tibio-talar effusion were found in 33% of ankles. Oligoarticular JIA patients had a higher rate of isolated tenosynovitis than did polyarticular JIA patients (56 and 29%, respectively). Medial ankle tendon involvement was more common in the oligoarthritis subgroup, whereas lateral ankle tenosynovitis was more common in the polyarthritis subgroup. More recently, the same group of investigators reassessed the clinical-US correlation in 61 swollen/painful ankles in 42 patients using a more accurate clinical examination protocol, which was focused not only on the tibio-talar joint, but also on medial and lateral tendons [28]. US demonstrated no signs of tibio-talar disease in 32% of the ankles considered clinically involved. Involvement of medial tendons was seen in 42% of ankles recorded as clinically normal. Less than 50% of the lateral tendons deemed to be clinically involved were affected on US. Very poor agreement was found comparing the clinical and US scores for the three regions. Poor agreement was observed also for subtalar joints, which were found to be abnormal on US in only 39% of instances classified as affected clinically.

Altogether, the results of these studies emphasize the ability of US to help clinicians to identify the precise site of inflammation, particularly in joint areas that are complex or difficult to evaluate clinically. Furthermore, they show that isolated tenosynovitis is frequently responsible for joint swelling in children with JIA. Notably, the definition of JIA categories in the ILAR classification does not take into consideration tendon involvement. Application of US may thus provide important insights into the location of inflammatory changes in different joints and possibly in diverse disease subtypes. These findings may offer the anatomical rationale for a future refinement of the classification of childhood arthritis.

Enthesitis

Enthesis inflammation is a recognized feature of JIA and affects mainly children with enthesitis-related arthritis, a disease subset characterized by the association of enthesitis and arthritis. The most frequently involved entheses are the calcaneal insertions of the Achilles tendon, the plantar fascia and the tarsal area [1]. In paediatric patients, the clinical identification of enthesitis inflammation is challenging because of the peculiar fat distribution that may mask the anatomical landmarks at the enthesitis insertion sites. Moreover, children often do not consistently

cooperate with the physician during clinical assessment. Hence the potential utility of a feasible, quick and simple tool, such as US, that may facilitate the recognition of clinical and subclinical forms of enthesitis.

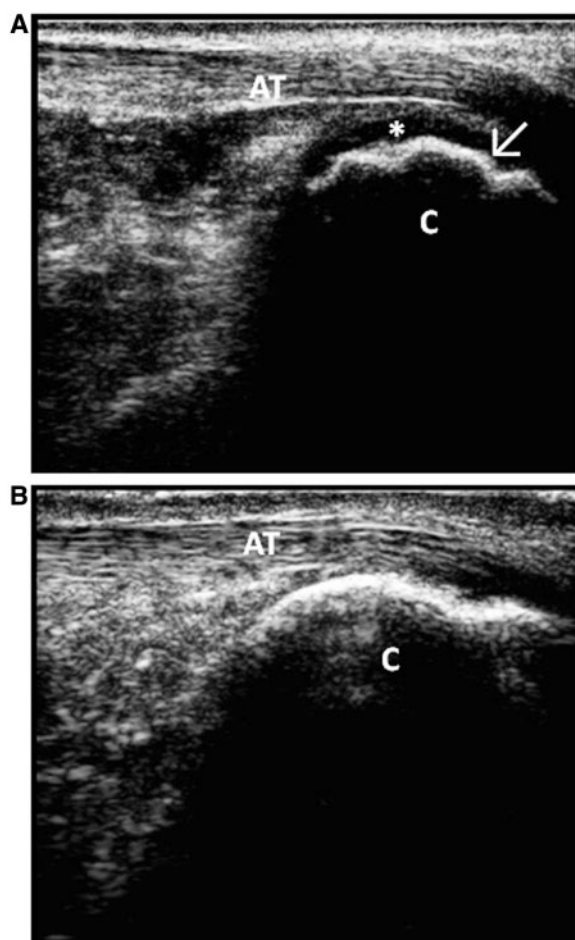
A recent study compared the accuracy of PD-US and physical evaluation in detecting enthesitis in 26 children with JIA and 41 healthy children [29]. The following enthesal sites were assessed: the proximal and distal quadriceps tendon insertions, the Achilles tendon and the plantar fascia. PD-US enthesitis was defined as the presence of a PD signal indicating abnormal vascularization at the insertion of the enthesis into the cortical bone. None of the enthesal sites of healthy children showed PD-US enthesitis. In JIA patients, although clinical enthesitis was often associated with PD-US enthesitis, the reverse was not true. In fact, 10 (50%) of the 20 sites exhibiting PD-US enthesitis were normal clinically. However, the clinical meaning of PD-US enthesitis without clinical evidence of enthesitis is unclear.

When evaluating enthesal inflammation in paediatric subjects, it should be taken into account that physiological cartilage vascularization of the ossification centres next to the enthesitis insertion sites can make it difficult, especially in younger children, to distinguish normal feeding from pathological inflammatory blood flow. In addition, the irregular shape of some ossification centres may be misinterpreted as a sign of enthesitis rather than as a normal age-related feature (Fig. 1). Experience and a thorough knowledge of the age-related changes of normal anatomy are essential for precise identification of enthesitis features in children.

Cartilage damage

Joint cartilage is a major target of the erosive process in chronic arthritis. The loss of US-detected cartilage may therefore be an early marker of joint damage in JIA. Radiographs do not directly visualize cartilage, and joint space narrowing is a relatively late finding. US is well suited for evaluation of the integrity of cartilage in the immature skeleton, as it is able to demonstrate the cartilage of unossified epiphyses and to capture the ossific nuclei much earlier than when it becomes visible radiographically. A recent study in healthy Caucasian children has found good agreement between MRI and US measurement of cartilage thickness, suggesting that US is a valid tool for assessing cartilage in JIA patients [30].

Using standard scans according to EULAR guidelines [31], Spannow *et al.* [32, 33] investigated the level of agreement between and within observers in the evaluation of cartilage thickness in several joints in healthy children. They found a satisfactory inter- and intra-observer agreement for all the examined joints, except for the wrist, where the variability was fairly high. The variability between assessors in the wrist may be explained in part by the marked abundance of cartilage in this joint in children, where large parts of the carpal bones may not be ossified yet. The same authors did not find differences in cartilage thickness between the left and right side in a healthy child population [33]. This observation suggests

Fig. 1 US of the Achilles tendon.

(A) Longitudinal scan of the Achilles tendon insertion in a 10-year-old healthy boy showing physiological bone irregularities (arrow). (B) US scan of the same anatomical area in a healthy adult subject (age 32 years). C: calcaneus; AT: Achilles tendon; *: cartilage. GE Healthcare Voluson i.

that the non-affected extremity may serve as a reference for evaluating cartilage damage in JIA patients. However, using the unaffected side as a reference can be problematic, as it can be affected subclinically. A more recent investigation in a large cohort of healthy children, aged between 7 and 16 years, led to the establishment of age- and sex-related normal standards for cartilage thickness in the knee, ankle, wrist, second MCP and second PIP joints. Furthermore, a formula was developed that enables calculation of cartilage thickness in the clinically dominant joints for children of all age groups [34]. These standards are of potential interest, as a decrease in cartilage thickness in JIA patients from the reference interval may be considered a signal of damage and disease progression. However, the statistical approach used in this study has been criticized [35]. Notably, it should be taken into account that cartilage thickness is affected by several non-disease-related factors, including maturation,

pubertal stage, height, weight and BMI [35]. The capacity of US to detect cartilaginous changes involving thinning [20] and blurring of the normally sharp margins [36] has also been reported in JIA.

Bone erosions

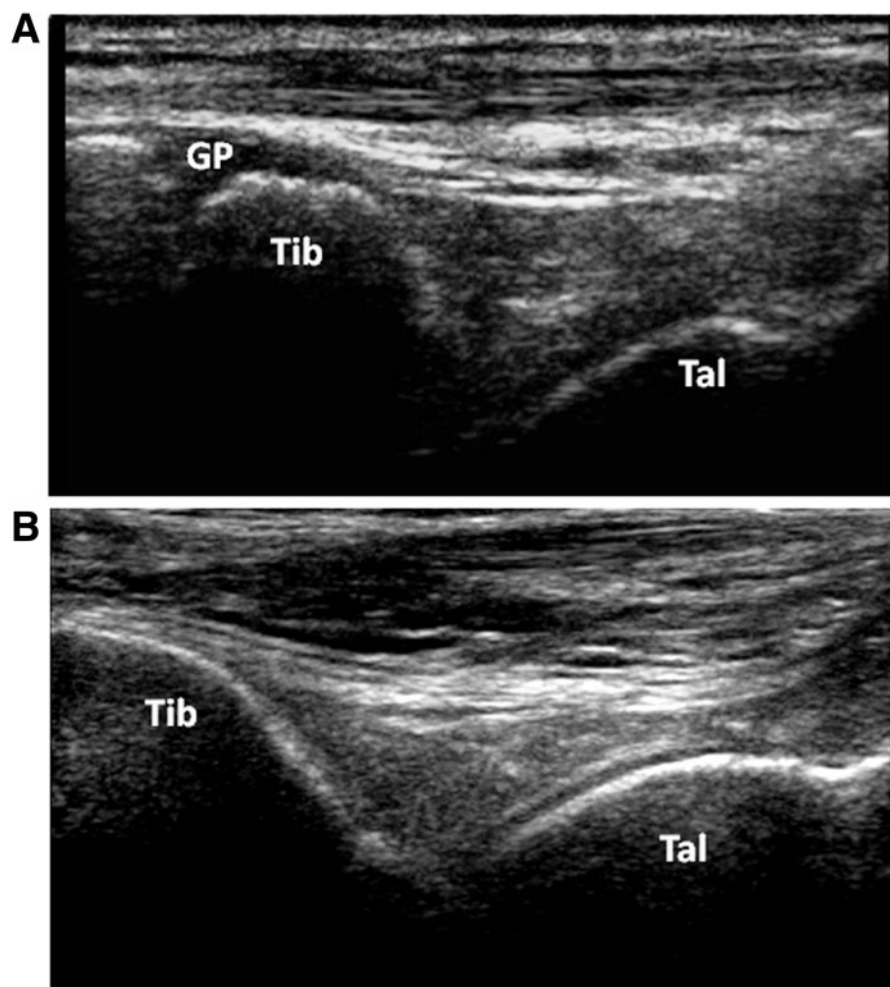
The capacity to assess joints dynamically, in real time, and in several planes makes US a powerful tool to detect bone erosions. To meet the OMERACT definition of erosion [12], an interruption of the bone surface visible in two perpendicular planes needs to be documented. In adult patients with RA, US was found to be more sensitive than conventional radiography in detecting early erosions [37]. The issue of assessment of bone erosions by US in children with JIA is virtually unexplored. However, the peculiar anatomy of growing children makes assessment of erosive changes challenging, owing to the presence of physiological bone irregularities in recently ossified bones, which can be misinterpreted as cortical erosions (Fig. 2). This potential shortcoming highlights the need to define normal bone anatomy throughout paediatric age groups on US before addressing the role of this imaging technique in assessing bone damage in JIA.

Comparison of US with MRI

Little information exists on the relative performance of US and MRI in the assessment of joint disease in children with JIA. This largely reflects the complexity and difficulty of conducting such studies in paediatric patients.

Malattia *et al.* [38] found that MRI was more sensitive than US in identifying early erosive changes in the clinically more affected wrist of children with JIA. This finding might be partially explained by the lower ability of US to explore less accessible and anatomically complex joints, such as the wrist, and by the choice of the investigators to scan only the dorsal aspect of the joint. However, longitudinal studies are needed to establish the real significance of bone erosions detected only by MRI, as changes resembling small bone erosions were recently documented in an MRI study of the wrists of healthy children [39].

El-Miedany *et al.* [40] evaluated the correlation between US and MRI in the assessment of the knee joint. Thirty-eight JIA patients with clinical involvement of the knee and a control group of 10 asymptomatic subjects underwent, in addition to plain radiography, US and MRI of the knee. MRI was performed before and after i.v. contrast injection. US was found to be less sensitive than MRI, as it was able to demonstrate fewer instances of effusion and synovial proliferation. As expected, MRI also proved superior in defining the extent of synovial proliferation and the amount of cartilage damage, especially after contrast administration. However, the limited feasibility of contrast-enhanced MRI makes this imaging method worthy of consideration only in selected cases and in the later stages of JIA, particularly when estimating the severity of structural joint changes.

Fig. 2 US of the tibio-talar joint.

(A) Longitudinal scan of the tibio-talar joint in a 10-year-old healthy boy showing the unossified cartilage of the growth plate of the tibial epiphysis. GE Healthcare Voluson i. **(B)** US scan of the same joint in a healthy adult subject (age 26 years). Philips iU22. Tib: tibia; Tal: talus; GP: growth plate.

Several comparative studies have addressed the assessment of temporomandibular joints (TMJs) in children with JIA. Weiss *et al.* [41] investigated the relative utility of US and MRI in the evaluation of acute and chronic TMJ changes in 32 new-onset patients. The two imaging techniques showed poor correlation, with US being less sensitive than MRI in the detection of TMJ disease. MRI was able to demonstrate acute arthritis in 24 (75%) patients, most of whom were asymptomatic and had normal physical examination, whereas none was detected by US. Chronic joint changes were found in 22 (69%) patients by MRI and in only 9 (28%) patients by US. Similar results were obtained by Müller *et al.* [42], who compared the performance of clinical examination, US and MRI in the early diagnosis of TMJ arthritis in 30 children. Patients underwent both rheumatological and orthodontic examination as well as US within 1 month of the MRI. US was found to be the least sensitive of all methods investigated and was found to be able to assess only the most severely

affected joints. Altogether, these findings suggest that, at present, US should not be considered as an accurate screening tool for the detection of early signs of TMJ disease in children with JIA. US is also of modest utility for assessment of the joints of the axial skeleton, namely the sacroiliac and vertebral joints.

US as a guide to local injection therapy

IAC injections are widely used in children with JIA to induce prompt relief of symptoms of active synovitis. To increase the chance of success of IAC therapy and minimize the risk of local side effects, namely s.c. atrophy, accurate placement of the needle within the joint space is essential. However, this can be difficult for certain joints that are not easy to assess clinically, such as the hip, subtalar, intertarsal or TMJs. Blinded injections are also challenging in younger children, due to the small joint size and the s.c. fat masking the bone landmarks. In these

instances, US can be valuable, as it helps the operator to place the needle tip accurately into the joint cavity. US could also assist in performing local injections in tendon sheaths or other periarticular structures.

The role of US in guiding IAC injections in the ankle region has been investigated recently [43]. Forty swollen ankles of 30 JIA patients were evaluated both clinically and with US before and 4 weeks after a US-guided IAC injection. At week 0, synovial hypertrophy, effusion and/or hyperaemia were found in 121 compartments by US, with multiple compartments being involved in most cases. Eighty-five of the 121 affected sites were injected using US guidance. Normalization or regression of synovial hypertrophy and hyperaemia was achieved in most cases and clinical absence of active disease was observed in 29/40 (72%) ankles 4 weeks after the injection. Parra *et al.* [44] evaluated the utility of US guidance to perform IAC injections in 180 TMJs of 83 children with JIA. Limited CT confirmation, used to check needle placement in 127 (70%) joints, confirmed correct IA placement of the needle tip in 115/127 (91%) cases. Only in 20 (16%) of the 115 procedures was a minor needle adjustment required. The favourable experience achieved so far underscores the need to support the training of paediatric rheumatologists in US-guided local injection procedures.

Summary and research agenda

US is gaining increasing interest among paediatric rheumatologists and it is anticipated that it will be used for ever more applications in the assessment of synovitis activity and response to treatment. However, several issues need to be addressed before widespread use of this imaging technique can be recommended.

First, the anatomical peculiarities of growing children make imaging interpretation more challenging than in adults. A thorough knowledge of paediatric US anatomy at different ages is essential to establish whether the observed changes are pathological or part of normal development. For instance, a positive PD signal at juxta-articular sites may reflect synovial hyperaemia related to an inflammatory process or may be an expression of the normal physiological flow inside the growth cartilage of the epiphysis. Furthermore, cartilage vascularization has been related to US synovitis [11], but can also be encountered in healthy children.

A great deal of effort should be exerted to standardize and validate the methodology for performing US and scoring its findings in children. As previously mentioned, the OMERACT definitions for US pathology in adults [12] may not be suitable for use in paediatric subjects. To overcome the gap of standardization and scientific knowledge between adult and paediatric rheumatology, a paediatric US subgroup within the OMERACT Ultrasound Task Force has been recently created. In addition, the EULAR has committed to involve paediatric rheumatologists in future activities on imaging.

An important question is how to accommodate the normal physiological joint changes in growing children in longitudinal assessments. To give an example,

improvement of a bone erosion may simply reflect the normal smoothing of the bone surface over time. In addition, a US scan of a particular joint in an individual child taken at initial evaluation may not be appropriate as the gold standard for comparison with subsequent scans obtained during follow-up. The rapidity of anatomic changes during growth, including the progressive replacement of cartilage with bone, may lead to a major change in the morphology of the joint and thus, hamper comparability with previous joint images.

Studies in adult patients with RA have led to US assessment of the extent of synovitis in a reduced number of joints, thereby shortening the length of US sessions [45, 46]. The use of reduced joint counts may be particularly advantageous in children, who are known to be less tolerant than adults to investigations. Hence the definition of the optimal number and pattern of joints that should be included in US assessment in children is warranted.

The operator dependence of US is a matter of particular concern in paediatric subjects. The reliability of US could be enhanced by the introduction of 3D equipment, which could lessen US operator dependence and enhance standardized acquisition of images [47]. Furthermore, the availability of smaller, handy and higher frequency probes could make small joint evaluation easier.

In summary, US has a great potential for use among paediatric rheumatologists, as it can be applied directly in the clinic. However, its use requires careful and continued training. Further studies are needed to enhance the reliability of US in JIA and to establish its validity in the assessment of therapeutic response and disease outcome.

Rheumatology key messages

- US is a powerful tool for the assessment of synovitis in JIA.
- US guidance may enhance the efficacy of local CS injection therapy in JIA.
- Additional studies are required to establish the reliability and validity of US in childhood arthritis.

Acknowledgements

S.L. is a recipient of the ARTICULUM Fellowship.

Disclosure statement: R.J.W. is a consultant for Abbott Laboratories. All other authors have declared no conflicts of interest.

References

- 1 Ravelli A, Martini A. Juvenile idiopathic arthritis. *Lancet* 2007;369:767–78.
- 2 Petty RE, Southwood TR, Manners P *et al.* International League of Associations for Rheumatology classification of juvenile idiopathic arthritis: second revision, Edmonton, 2001. *J Rheumatol* 2004;31:390–2.

- 3 Ruperto N, Martini A. Emerging drugs to treat juvenile idiopathic arthritis. *Expert Opin Emerg Drugs* 2011;16: 493–505.
- 4 Magni-Manzoni S, Malattia C, Lanni S, Ravelli A. Advances and challenges in imaging in juvenile idiopathic arthritis. *Nat Rev Rheumatol* 2012;8:329–36.
- 5 Filippucci E, Iagnocco A, Meenagh G *et al*. Ultrasound imaging for the rheumatologist VII. Ultrasound imaging in rheumatoid arthritis. *Clin Exp Rheumatol* 2007;25:5–10.
- 6 Brown AK, Quinn MA, Karim Z *et al*. Presence of significant synovitis in rheumatoid arthritis patients with disease-modifying antirheumatic drug-induced clinical remission: evidence from an imaging study may explain structural progression. *Arthritis Rheum* 2006;54:3761–73.
- 7 Walther M, Harms H, Krenn V *et al*. Synovial tissue of the hip at power Doppler US: correlation between vascularity and power Doppler US signal. *Radiology* 2002;225: 225–31.
- 8 Albrecht K, Müller-Ladner U, Strunk J. Quantification of the synovial perfusion in rheumatoid arthritis using Doppler ultrasonography. *Clin Exp Rheumatol* 2007;25: 630–8.
- 9 Spârchez M, Fodor D, Miu N. The role of power Doppler ultrasonography in comparison with biological markers in the evaluation of disease activity in juvenile idiopathic arthritis. *Med Ultrason* 2010;12:97–103.
- 10 Shahin AA, Shaker OG, Kamal N *et al*. Circulating interleukin-6, soluble interleukin-2 receptors, tumor necrosis factor alpha, and interleukin-10 levels in juvenile chronic arthritis: correlations with soft tissue vascularity assessed by power Doppler sonography. *Rheumatol Int* 2002;22:84–8.
- 11 Breton S, Jousse-Joulin S, Cangemi C *et al*. Comparison of clinical and ultrasonographic evaluations for peripheral synovitis in juvenile idiopathic arthritis. *Semin Arthritis Rheum* 2011;41:272–8.
- 12 Wakefield RJ, Balint PV, Szkudlarek M *et al*. Musculoskeletal ultrasound including definitions for ultrasonographic pathology. *J Rheumatol* 2005;32:2485–7.
- 13 Wakefield RJ, Green MJ, Marzo-Ortega H *et al*. Should oligoarthritis be reclassified? Ultrasound reveals a high prevalence of subclinical disease. *Ann Rheum Dis* 2004; 63:382–5.
- 14 Cellierini M, Salti S, Trapani S *et al*. Correlation between clinical and ultrasound assessment of the knee in children with mono-articular or pauci-articular juvenile rheumatoid arthritis. *Pediatr Radiol* 1999;29:117–23.
- 15 Kraan MC, Patel DD, Haringman JJ *et al*. The development of clinical signs of rheumatoid synovial inflammation is associated with increased synthesis of the chemokine CXCL8 (interleukin-8). *Arthritis Res* 2001;3:65–71.
- 16 Guzmán J, Burgos-Vargas R, Duarte-Salazar C, Gómez-Mora P. Reliability of the articular examination in children with juvenile rheumatoid arthritis: interobserver agreement and sources of disagreement. *J Rheumatol* 1995;22: 2331–6.
- 17 Filer A, de Pablo P, Allen G *et al*. Utility of ultrasound joint counts in the prediction of rheumatoid arthritis in patients with very early synovitis. *Ann Rheum Dis* 2011;70: 500–7.
- 18 Magni-Manzoni S, Epis O, Ravelli A *et al*. Comparison of clinical versus ultrasound-determined synovitis in juvenile idiopathic arthritis. *Arthritis Rheum* 2009;61:1497–504.
- 19 Haslam KE, McCann LJ, Wyatt S, Wakefield RJ. The detection of subclinical synovitis by ultrasound in oligoarticular juvenile idiopathic arthritis: a pilot study. *Rheumatology* 2010;49:123–7.
- 20 Karmazyn B, Bowyer SL, Schmidt KM *et al*. US findings of metacarpophalangeal joints in children with idiopathic juvenile arthritis. *Pediatr Radiol* 2007;37:475–82.
- 21 Wallace CA, Giannini EH, Huang B, Irtter L, Ruperto N. American College of Rheumatology provisional criteria for defining clinical inactive disease in select categories of juvenile idiopathic arthritis. *Arthritis Care Res* 2011;63: 929–36.
- 22 Brown AK, Conaghan PG, Karim Z *et al*. An explanation for the apparent dissociation between clinical remission and continued structural deterioration in rheumatoid arthritis. *Arthritis Rheum* 2008;58:2958–67.
- 23 Rebollo-Polo M, Koujok K, Weisser C *et al*. Ultrasound findings on patients with juvenile idiopathic arthritis in clinical remission. *Arthritis Care Res* 2011;63:1013–9.
- 24 Magni-Manzoni S, Sciré CA, Ravelli A *et al*. Ultrasound-detected synovial abnormalities are frequent in clinically inactive juvenile idiopathic arthritis, but do not predict a flare of synovitis. *Ann Rheum Dis* 2012, Advance Access published 26 June 2012, doi: 10.1136/annrheumdis-2011-201264.
- 25 Sciré CA, Montecucco C, Codullo V *et al*. Ultrasonographic evaluation of joint involvement in early rheumatoid arthritis in clinical remission: power Doppler signal predicts short-term relapse. *Rheumatology* 2009;48:1092–7.
- 26 Peluso G, Michelutti A, Bosello S *et al*. Clinical and ultrasonographic remission determines different chances of relapse in early and long standing rheumatoid arthritis. *Ann Rheum Dis* 2011;70:172–5.
- 27 Rooney ME, McAllister C, Burns JF. Ankle disease in juvenile idiopathic arthritis: ultrasound findings in clinically swollen ankles. *J Rheumatol* 2009;36:1725–9.
- 28 Pascoli L, Wright S, McAllister C, Rooney M. Prospective evaluation of clinical and ultrasound findings in ankle disease in juvenile idiopathic arthritis: importance of ankle ultrasound. *J Rheumatol* 2010;37:2409–14.
- 29 Jousse-Joulin S, Breton S, Cangemi C *et al*. Ultrasonography for detecting enthesitis in juvenile idiopathic arthritis. *Arthritis Care Res* 2011;63:849–55.
- 30 Spannow AH, Stenboeg E, Pfeiffer-Jensen M *et al*. Ultrasound and MRI measurements of joint cartilage in healthy children: a validation study. *Ultraschall Med* 2011; 32(Suppl. 1):S110–6.
- 31 Backhaus M, Burmester GR, Gerber T *et al*. Guidelines for musculoskeletal ultrasound in rheumatology. *Ann Rheum Dis* 2001;60:641–9.
- 32 Spannow AH, Stenboeg E, Pfeiffer-Jensen M, Herlin T. Ultrasound measurement of joint cartilage thickness in large and small joints in healthy children: a clinical pilot study assessing observer variability. *Pediatr Rheumatol Online J* 2007;5:3.
- 33 Spannow AH, Pfeiffer-Jensen M, Andersen NT, Stenbøeg E, Herlin T. Inter- and intraobserver variation of

- ultrasonographic cartilage thickness assessments in small and large joints in healthy children. *Pediatr Rheumatol Online J* 2009;7:12.
- 34 Spannow AH, Pfeiffer-Jensen M, Andersen NT, Herlin T, Stenbøg E. Ultrasonographic measurements of joint cartilage thickness in healthy children: age- and sex-related standard reference values. *J Rheumatol* 2010;37:2595–601.
 - 35 Larché MJ, Roth J. Toward standardized ultrasound measurements of cartilage thickness in children. *J Rheumatol* 2010;37:2445–7.
 - 36 Sureda D, Quiroga S, Arnal C *et al.* Juvenile rheumatoid arthritis of the knee: evaluation with US. *Radiology* 1994;190:403–6.
 - 37 Wakefield RJ, Gibbon WW, Conaghan PG *et al.* The value of sonography in the detection of bone erosions in patients with rheumatoid arthritis: a comparison with conventional radiography. *Arthritis Rheum* 2000;43:2762–70.
 - 38 Malattia C, Damasio MB, Magnaguagno F *et al.* Magnetic resonance imaging, ultrasonography, and conventional radiography in the assessment of bone erosions in juvenile idiopathic arthritis. *Arthritis Rheum* 2008;59:1764–72.
 - 39 Müller LS, Avenarius D, Damasio B *et al.* The paediatric wrist revisited: redefining MR findings in healthy children. *Ann Rheum Dis* 2011;70:605–10.
 - 40 El-Miedany YM, Housny IH, Mansour HM *et al.* Ultrasound versus MRI in the evaluation of juvenile idiopathic arthritis of the knee. *Joint Bone Spine* 2001;68:222–30.
 - 41 Weiss PF, Arabshahi B, Johnson A *et al.* High prevalence of temporomandibular joint arthritis at disease onset in children with juvenile idiopathic arthritis, as detected by magnetic resonance imaging but not by ultrasound. *Arthritis Rheum* 2008;58:1189–96.
 - 42 Müller L, Kellenberger CJ, Cannizzaro E *et al.* Early diagnosis of temporomandibular joint involvement in juvenile idiopathic arthritis: a pilot study comparing clinical examination and ultrasound to magnetic resonance imaging. *Rheumatology* 2009;48:680–5.
 - 43 Laurell L, Court-Payen M, Nielsen S *et al.* Ultrasonography and color Doppler in juvenile idiopathic arthritis: diagnosis and follow-up of ultrasound-guided steroid injection in the ankle region. A descriptive interventional study. *Pediatr Rheumatol Online J* 2011;9:4.
 - 44 Parra DA, Chan M, Krishnamurthy G *et al.* Use and accuracy of US guidance for image-guided injections of the temporomandibular joints in children with arthritis. *Pediatr Radiol* 2010;40:1498–504.
 - 45 Naredo E, Gamero F, Bonilla G *et al.* Ultrasonographic assessment of inflammatory activity in rheumatoid arthritis: comparison of extended versus reduced joint evaluation. *Clin Exp Rheumatol* 2005;23:881–4.
 - 46 Naredo E, Rodríguez M, Campos C *et al.* Validity, reproducibility, and responsiveness of a twelve-joint simplified power doppler ultrasonographic assessment of joint inflammation in rheumatoid arthritis. *Arthritis Rheum* 2008;59:515–22.
 - 47 Filippucci E, Meenagh G, Epis O *et al.* Ultrasound imaging for the rheumatologist. XIII. New trends. Three-dimensional ultrasonography. *Clin Exp Rheumatol* 2008;26:1–4.